



From Global Strategy to National Action: Workshop for Health Service Managers in Charge of Leprosy Control Programmes

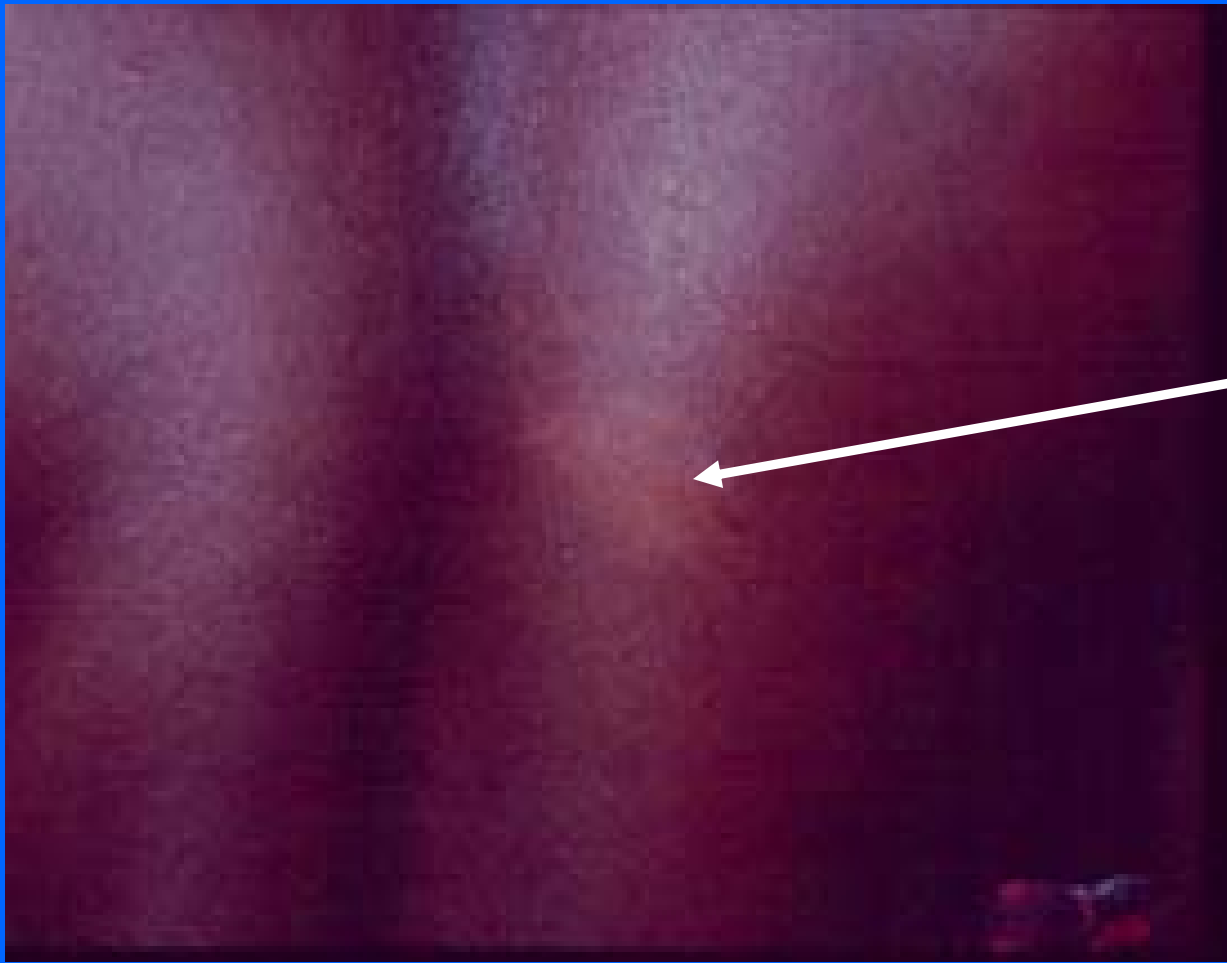
Session 2 Part 2 Diagnosis

Topic: Diagnosis and differential diagnosis



Expectations:

- The following set of slides depicts cases of leprosy and other skin conditions that should be considered in the differential diagnosis of leprosy.
- For each slide
 - ✓ State what other information you would need
 - ✓ Try to decide if the case is leprosy or not, and give reasons for it.
 - ✓ If it is leprosy, state the classification
 - ✓ If it is not leprosy, say what else it might be.



Clear macule,
with irregular
edge and
normal skin
consistency,
present since
childhood

- ✓ Leprosy?
- ✓ PB or MB?
- ✓ Other diagnosis?

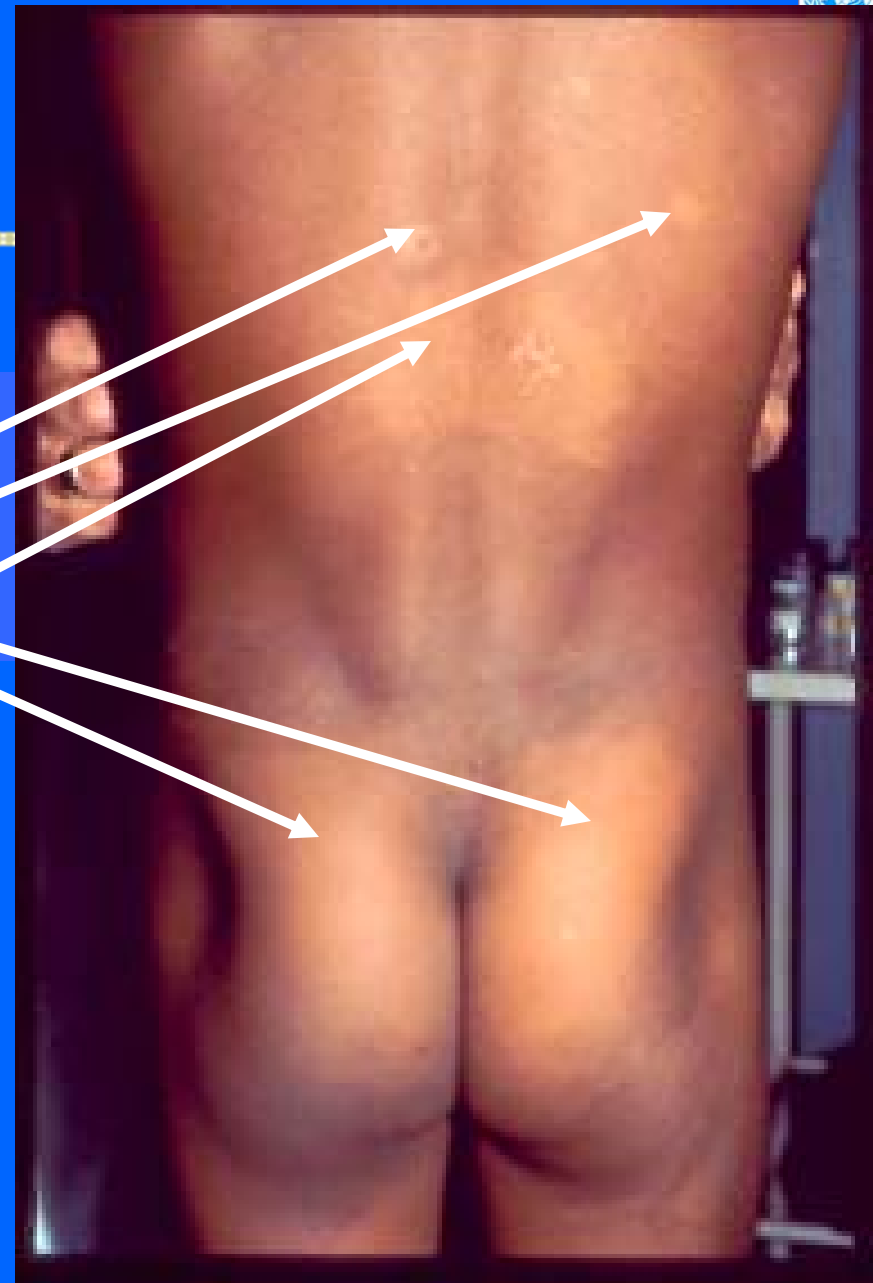Answer: Birth mark (Naevus anemicus)

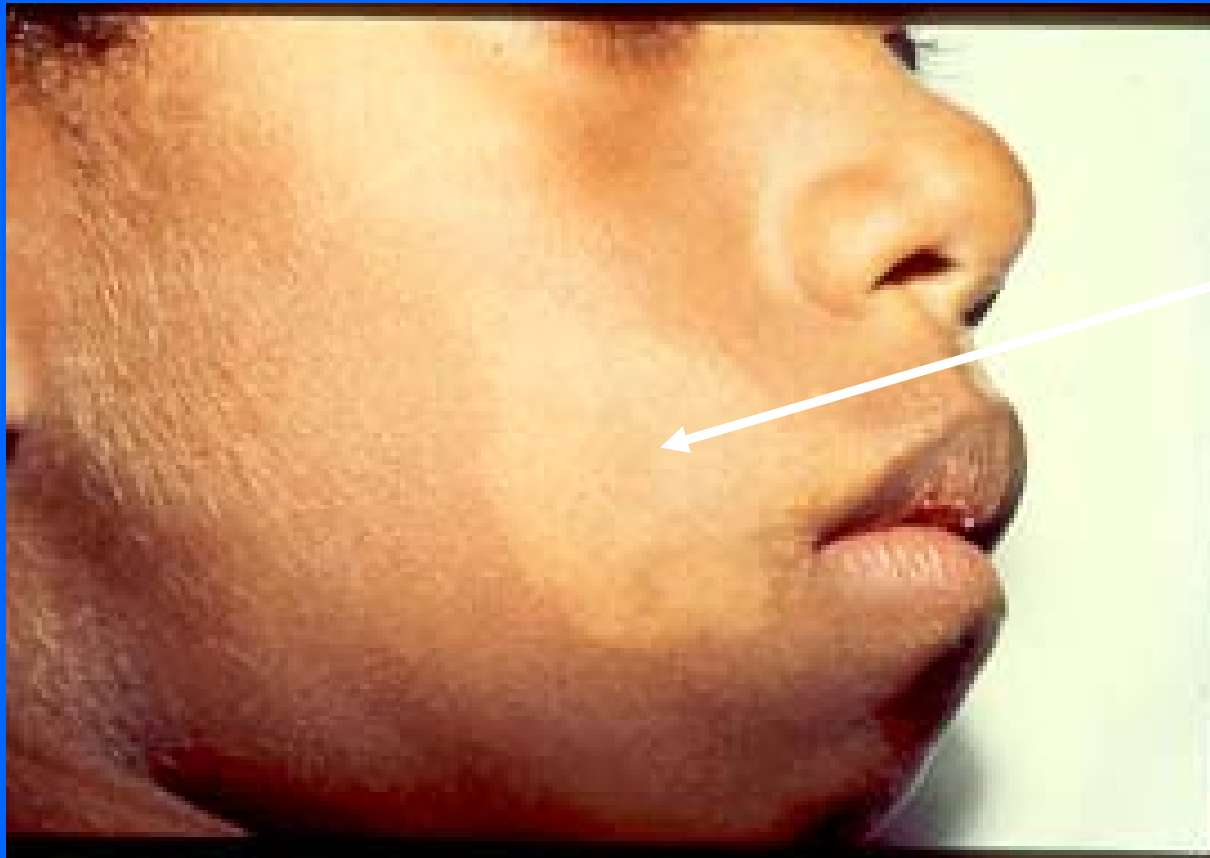

Multiple clear patches, some with satellite lesions and loss of sensation.

- ✓ Leprosy?
- ✓ PB or MB?
- ✓ Other diagnosis?

Answer:
MB leprosy clinically but bacteriologically PB

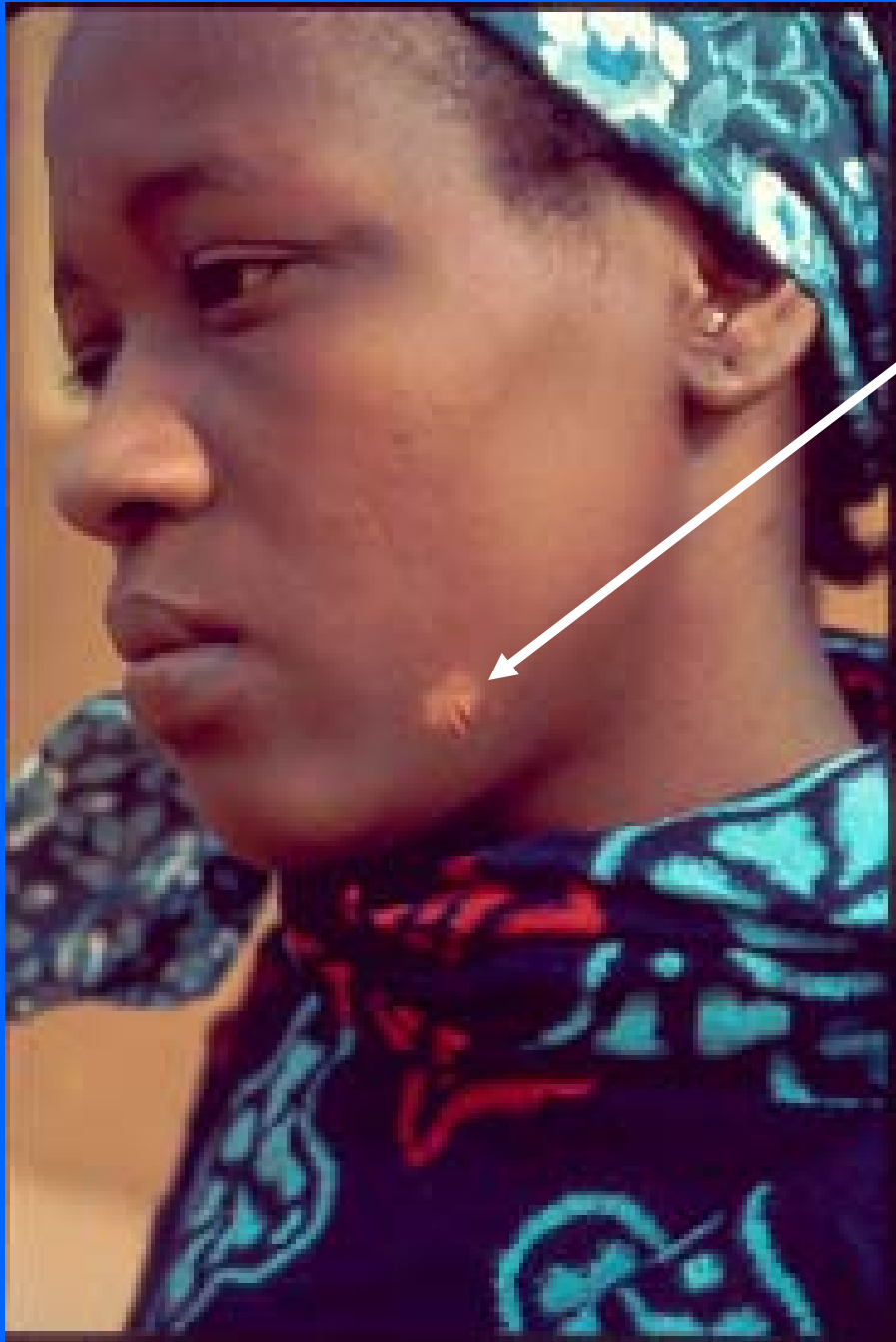



**Hypopigmented
macule**

- ✓ **Leprosy?**
- ✓ **PB or MB?**
- ✓ **Other diagnosis?**

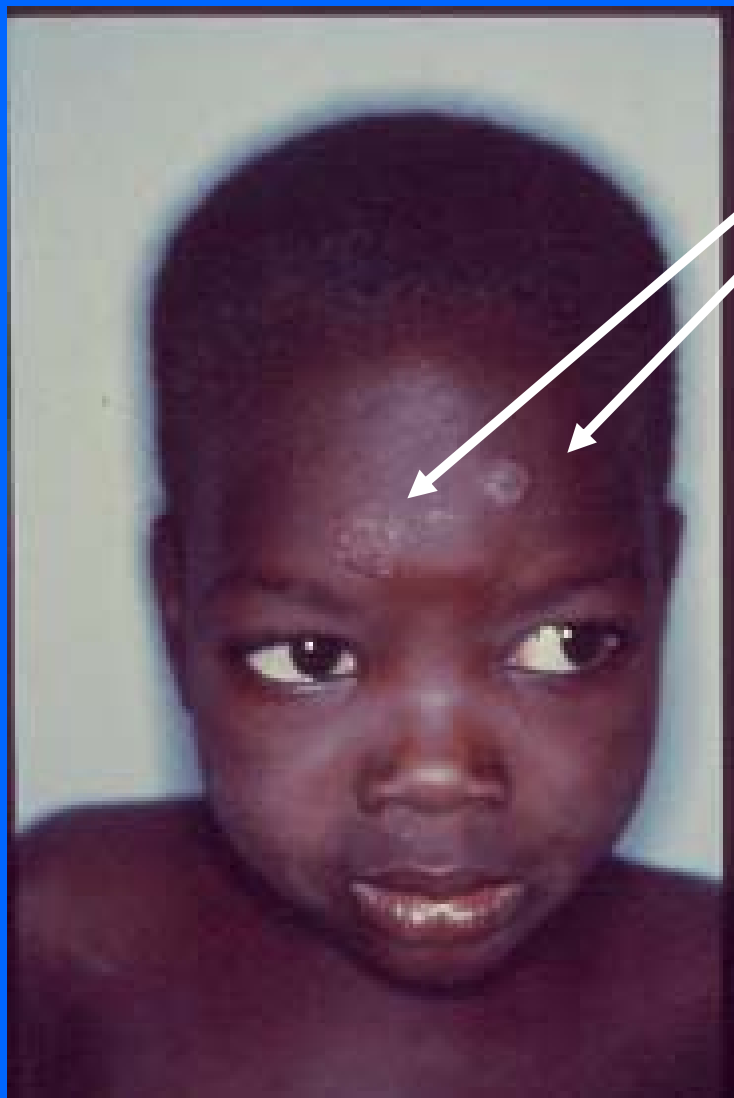Answer: PB leprosy in a child



Single hypo pigmented macule

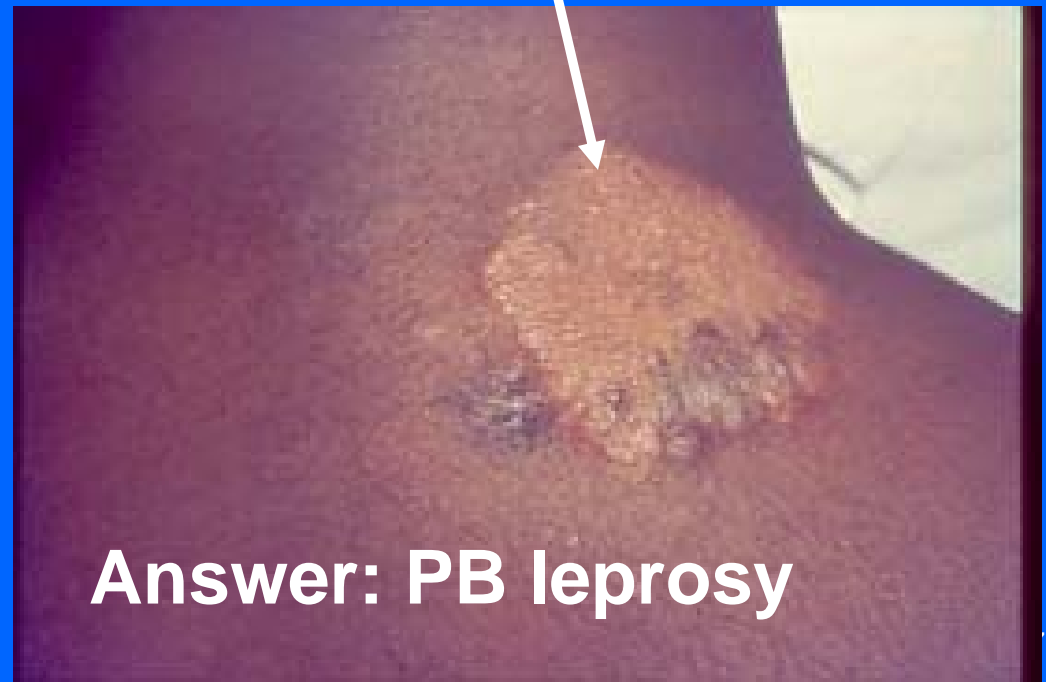- ✓ **Leprosy?**
- ✓ **PB or MB?**
- ✓ **Other diagnosis?**

Answer: PB leprosy



2 hypopigmented lesions with raised borders.

1 well defined raised lesion with some central healing

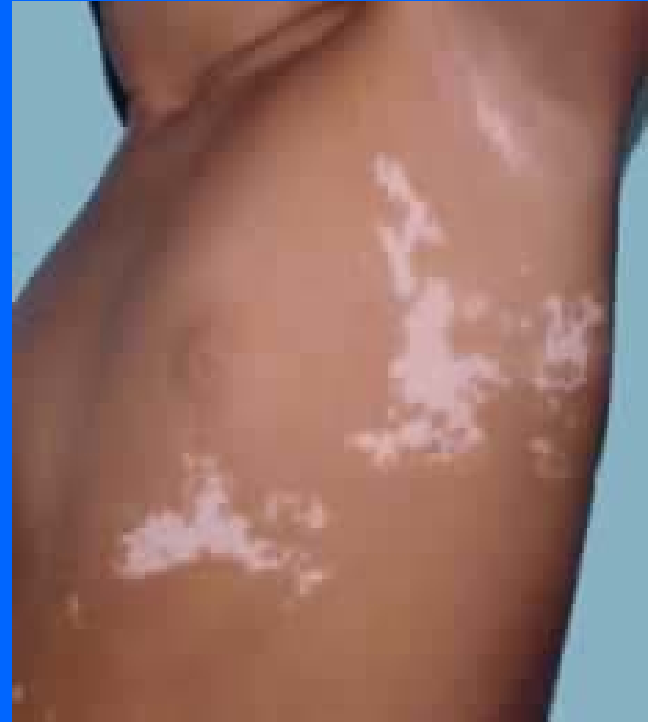
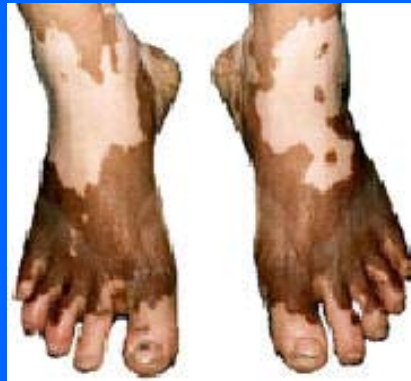
- ✓ Leprosy?
- ✓ PB or MB?
- ✓ Other diagnosis?

Answer: PB leprosy



Depigmented macules with no loss of sensation

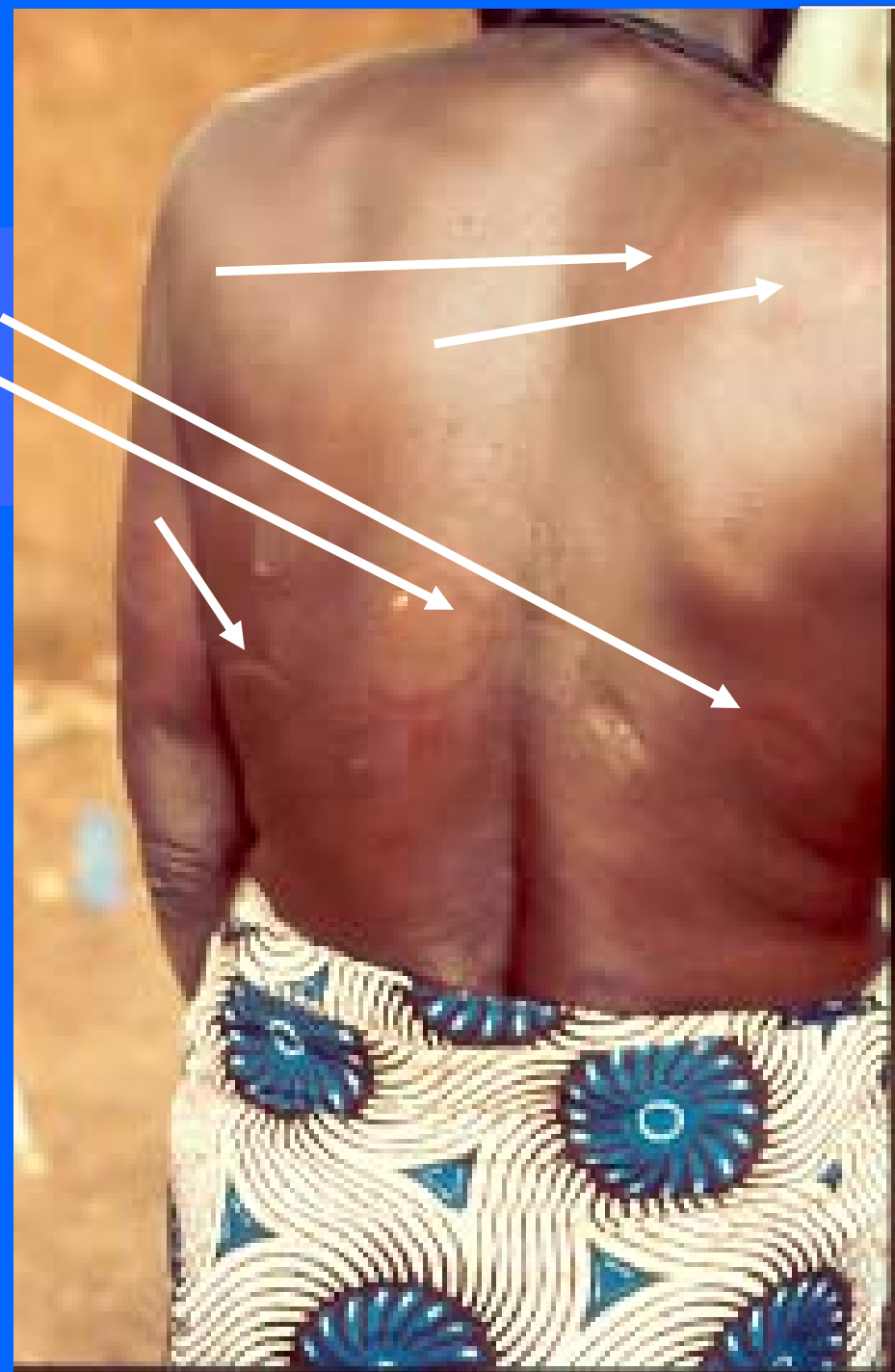


Vitiligo

Several hypopigmented lesions with infiltrated borders

- ✓ Leprosy?
- ✓ PB or MB?
- ✓ Other diagnosis?

Answer: MB leprosy

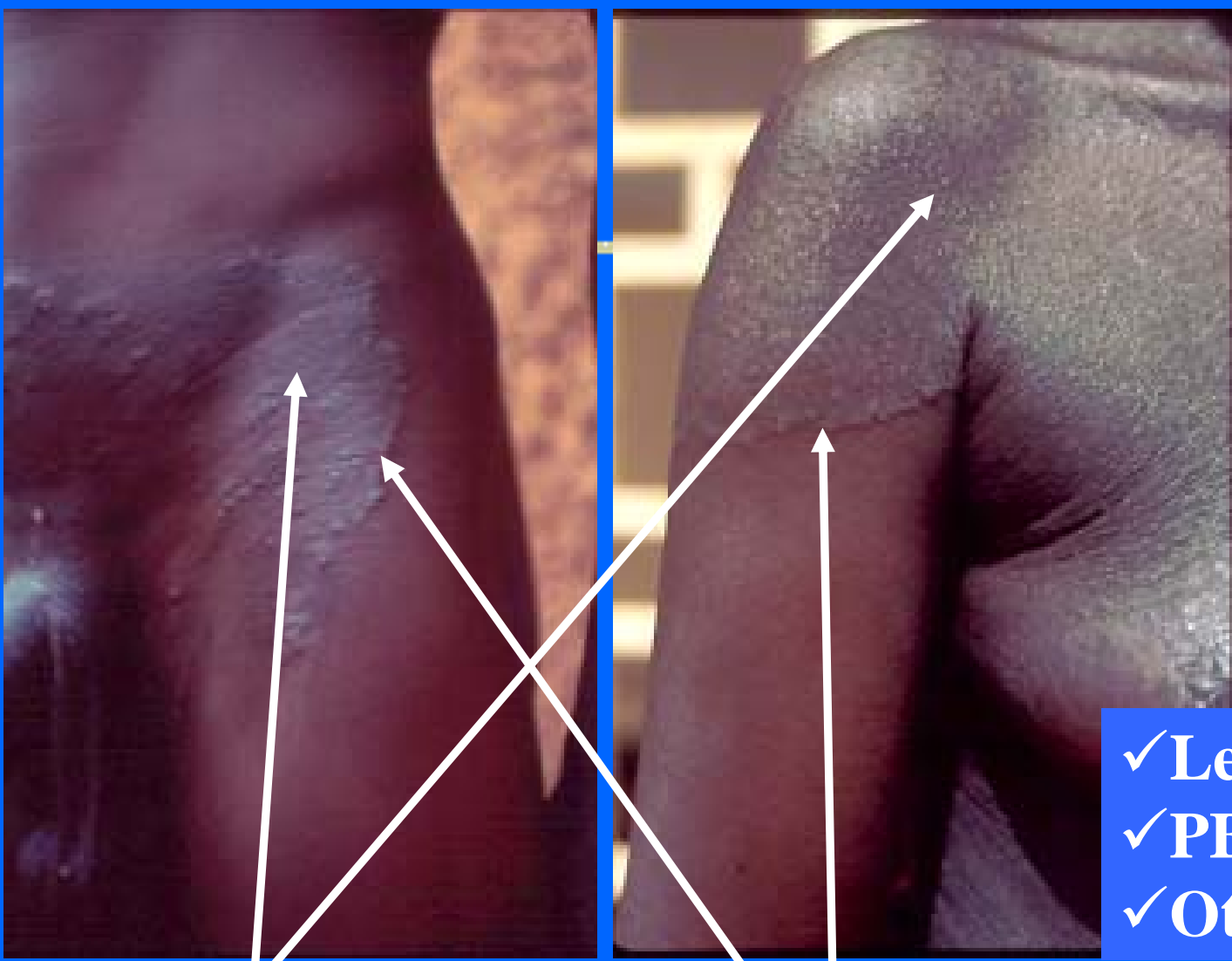




One large hypopigmented lesion with several raised smaller ones.

- ✓ Leprosy?
- ✓ PB or MB?
- ✓ Other diagnosis?

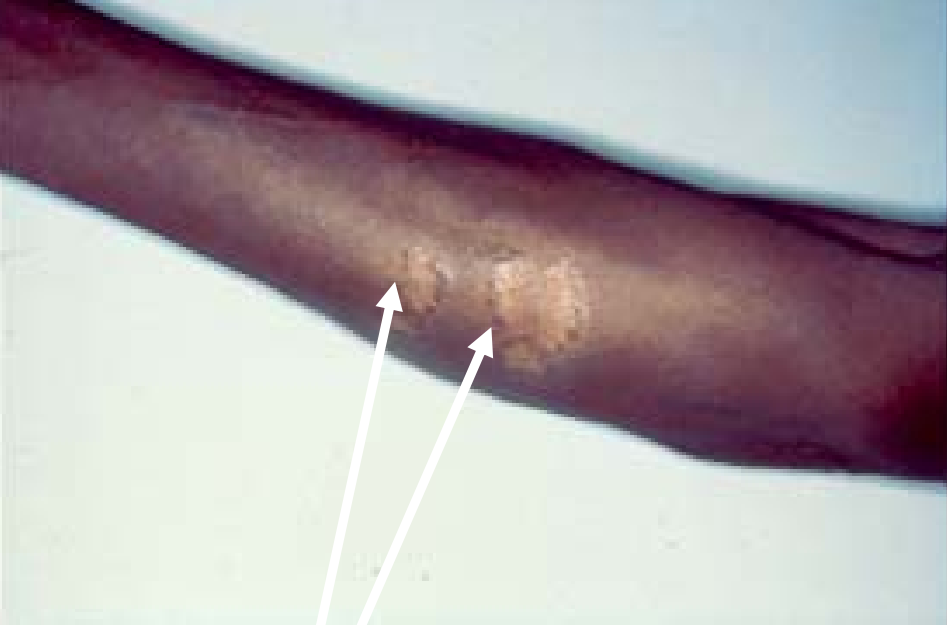Answer: MB leprosy



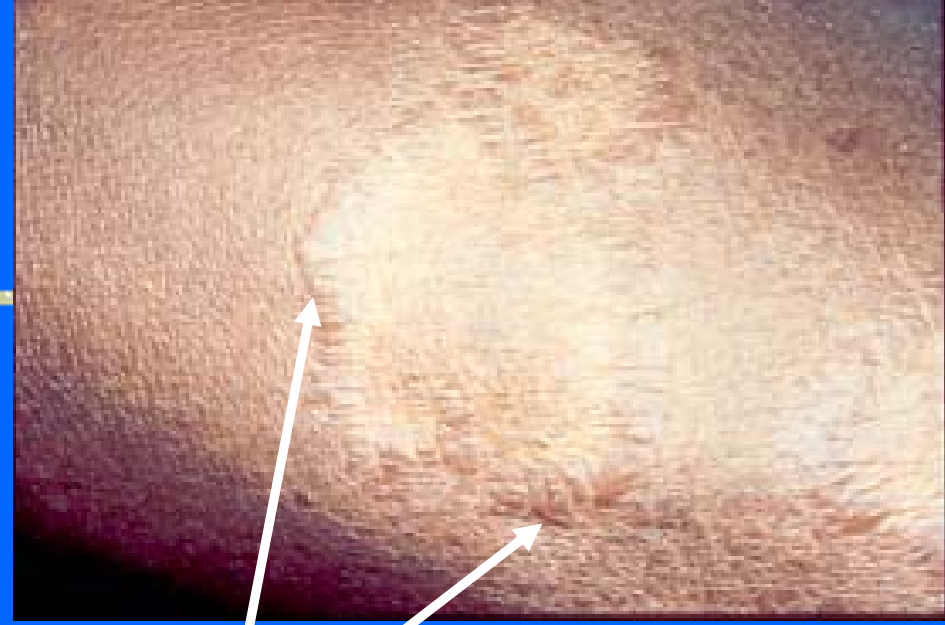Pigmented patches with raised vesicular borders. Itching.

- ✓ Leprosy?
- ✓ PB or MB?
- ✓ Other diagnosis?

**Answer:
Fungus infection**



2 lesions on the arm with raised papular borders.



Detail of one of the lesions showing the papular border

- ✓ Leprosy?
- ✓ PB or MB?
- ✓ Other diagnosis?

Answer: PB leprosy

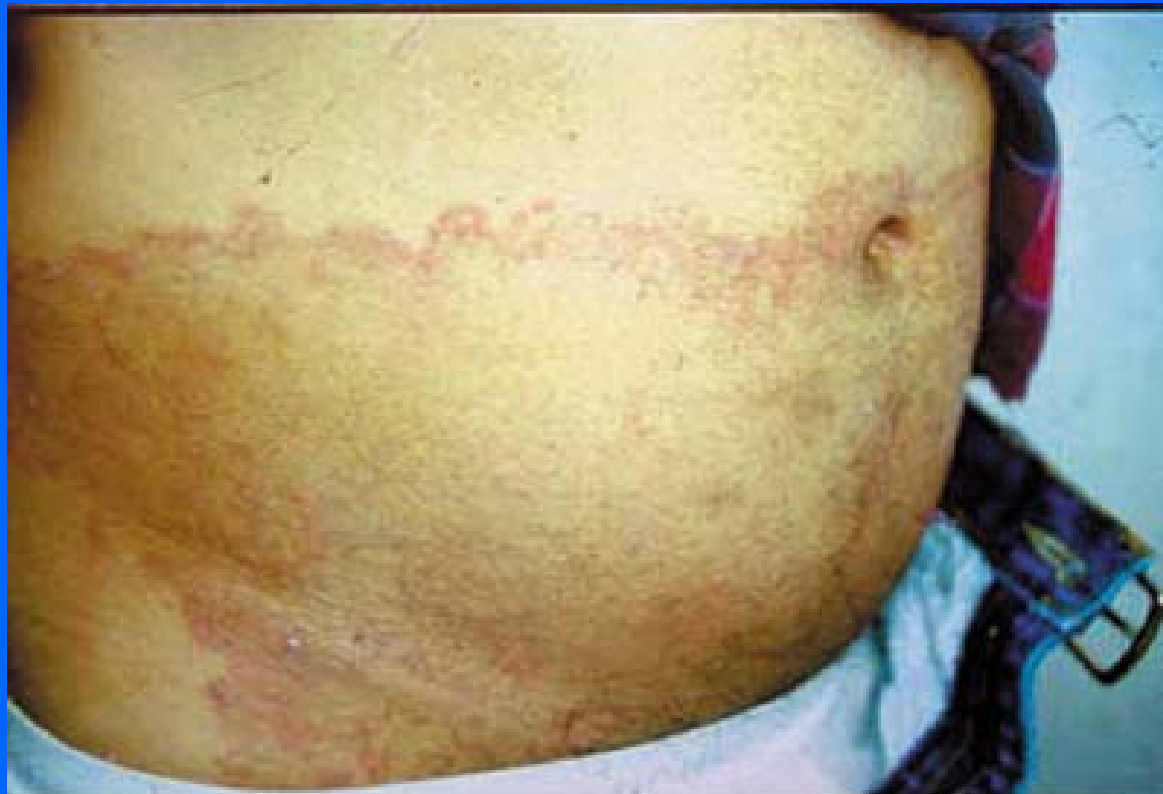

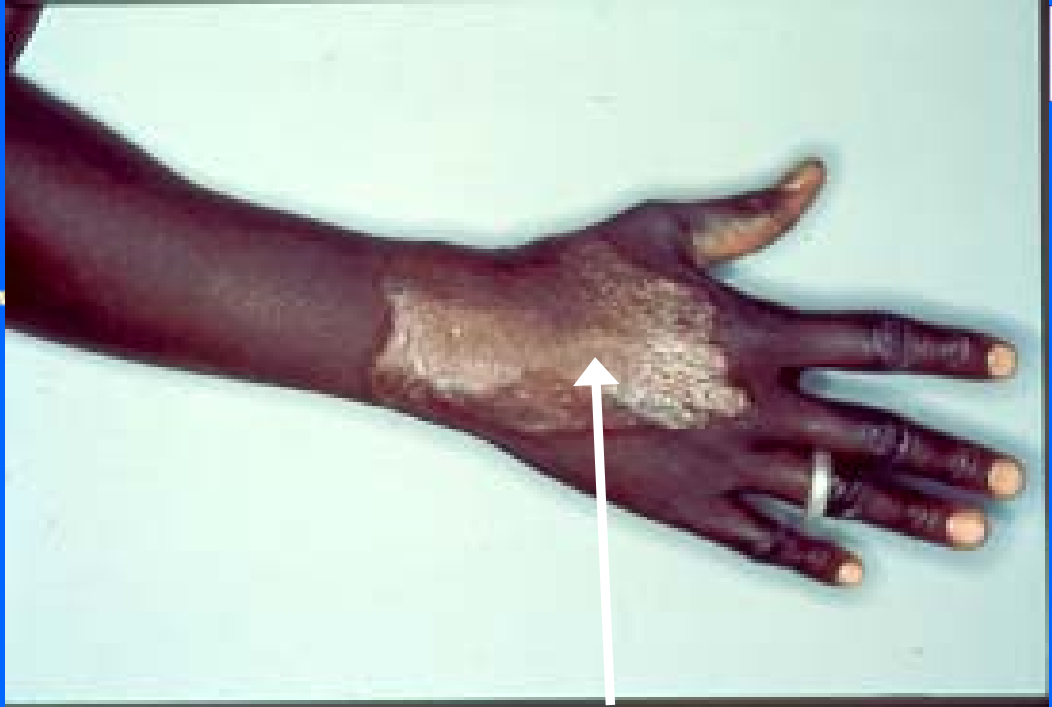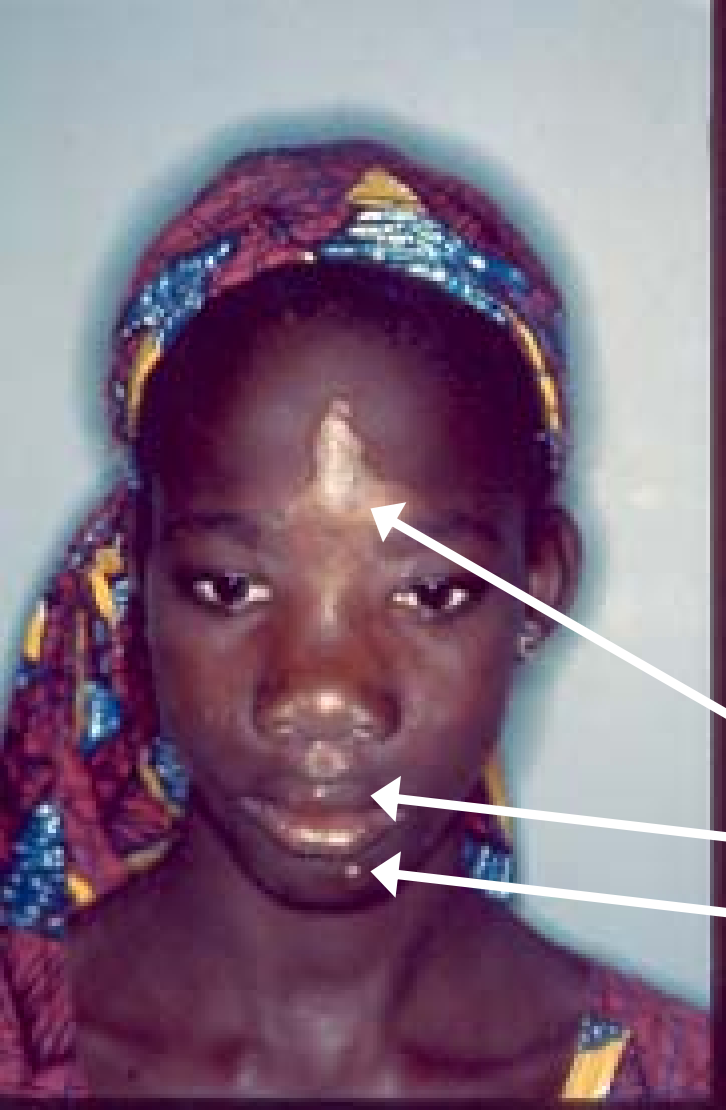Fig. 70. Tinea Corporis



Depigmented lesion with butterfly pattern distribution

- ✓ Leprosy?
- ✓ PB or MB?
- ✓ Other diagnosis?

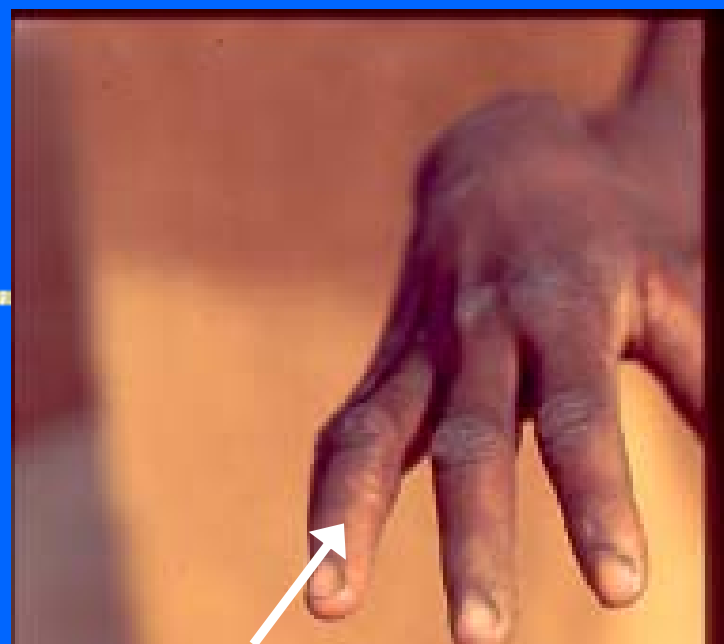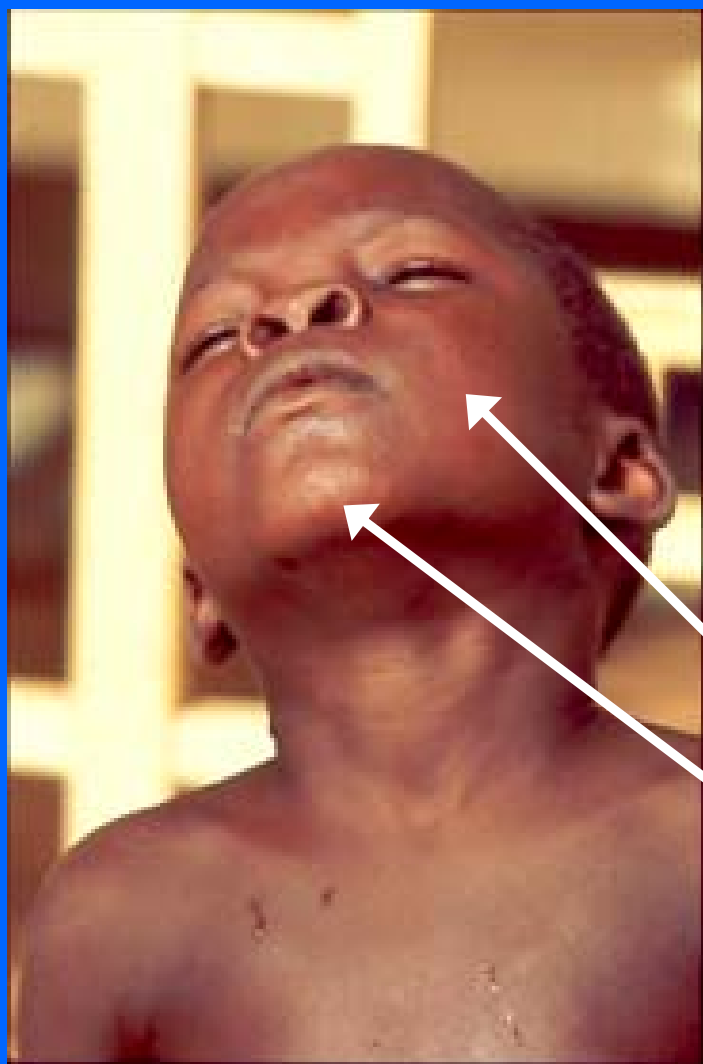Answer: Lupus Erythematosus



Raised lesions in centre of the face and hand of a young lady. Nodule like lesions on the lips and chin. Definite loss of sensation. Skin smear negative.

- ✓ Leprosy?
- ✓ PB or MB?
- ✓ Other diagnosis?

Answer: Clinically MB Leprosy



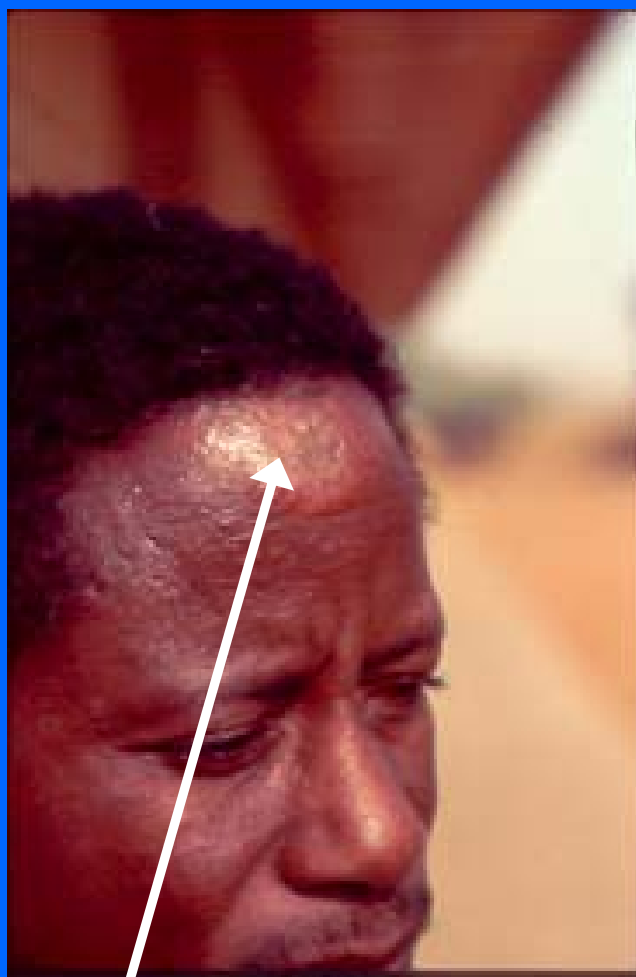Child with hypopigmented facial lesion with no loss of sensation. Nodules on chin and the fingers. History of leprosy contact. Skin smears positive.

✓ Leprosy?

✓ PB or MB?

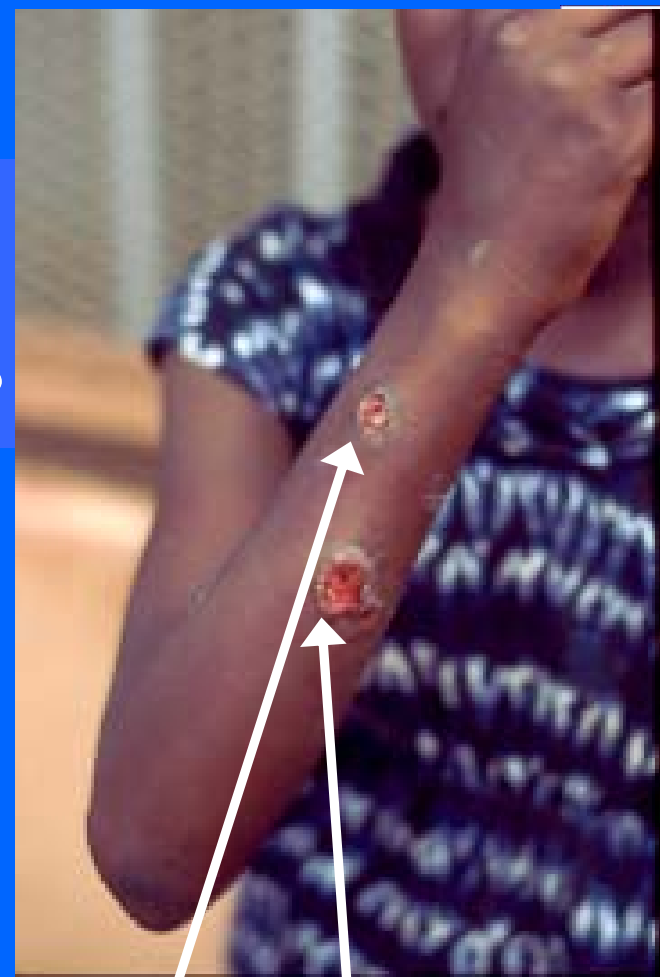✓ Other diagnosis?

Answer: MB leprosy



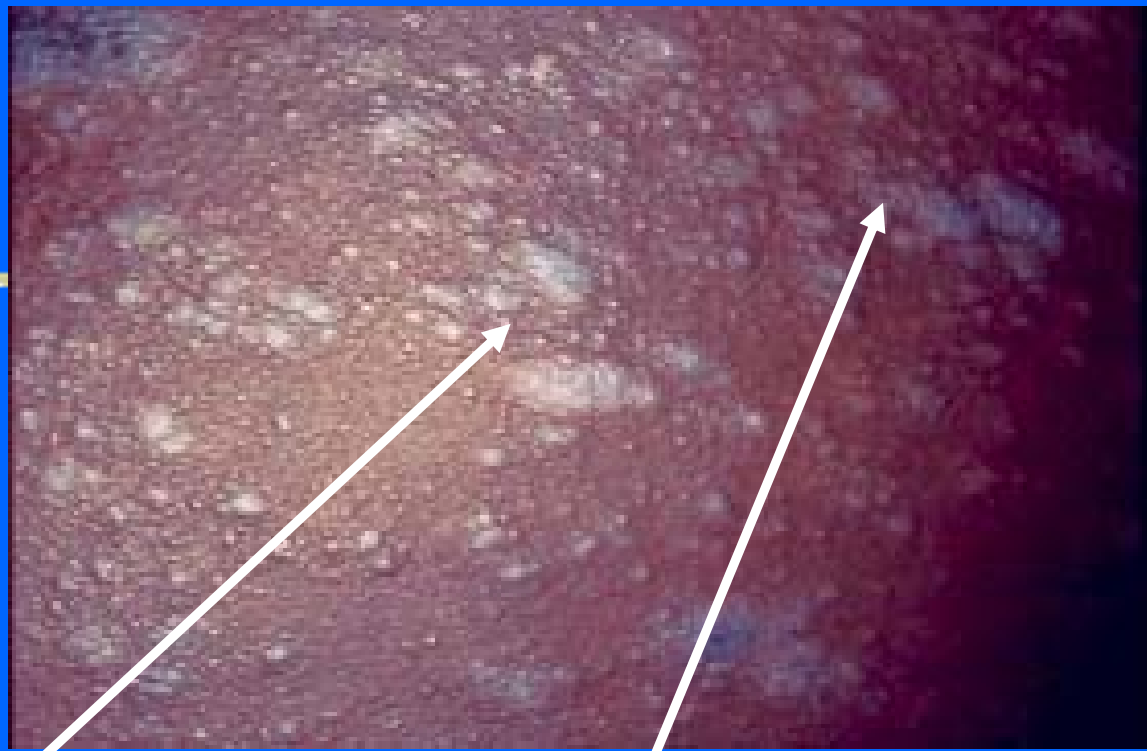
- ✓ Leprosy?
- ✓ PB or MB?
- ✓ Other diagnosis?

**Answer:
Cutaneous
leishmaniasis**



**Raised erythematous
lesion on the forehead
that is extending
outwards and getting
ulcerated.**

**Lesions that are
already ulcerated
and discharging pus**



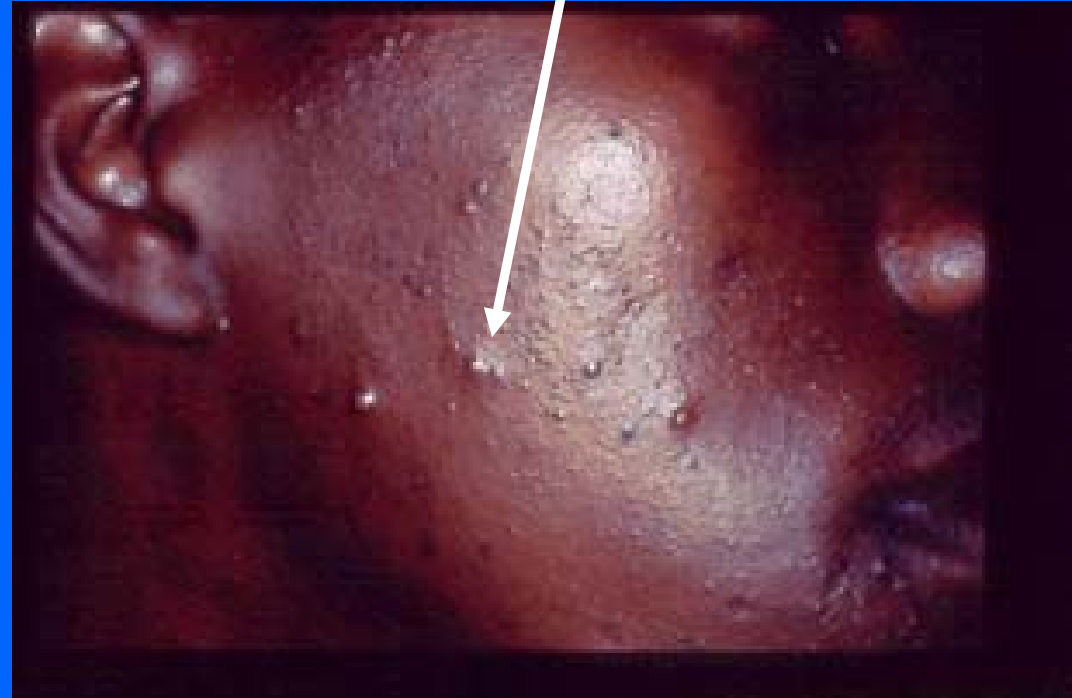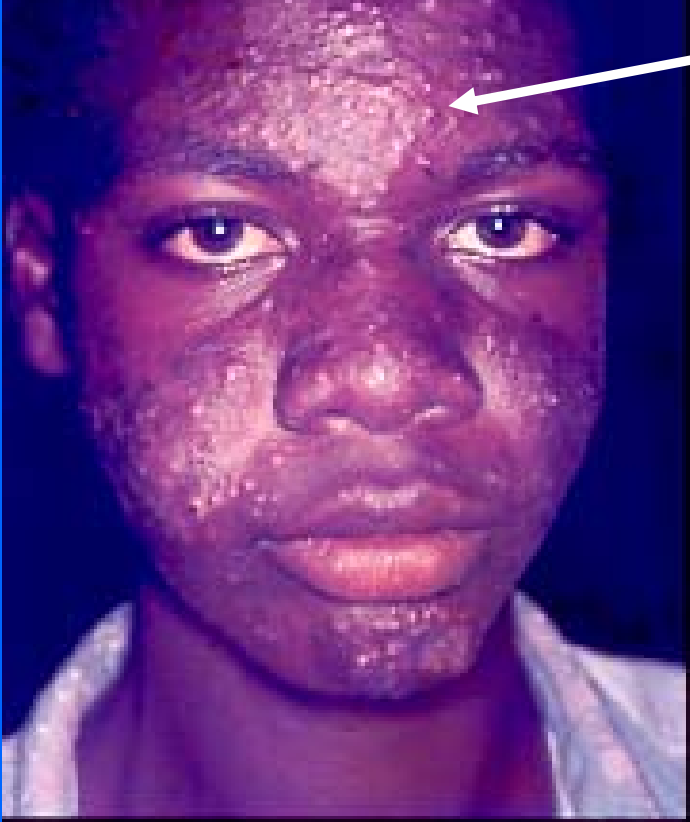Flat topped shiny papules on the trunk that are very itchy. Often with bluish black colour

- ✓ Leprosy?
- ✓ PB or MB?
- ✓ Other diagnosis?

Answer: Lichen planus

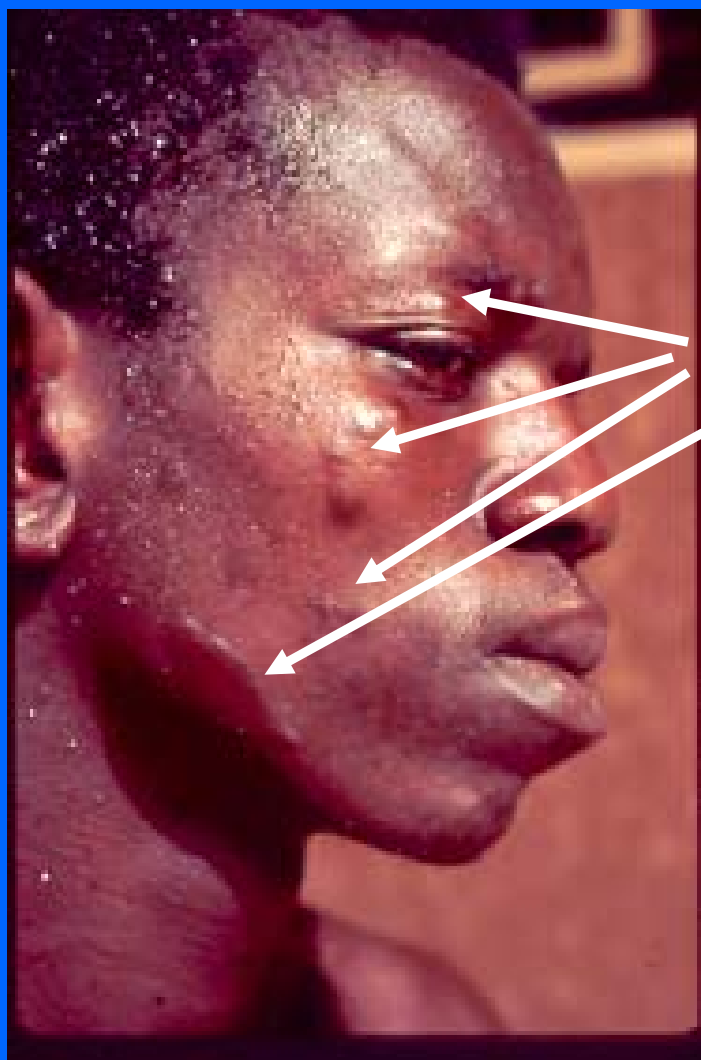

Papules and pustules in different stages. Common in the sebaceous areas of the faces off adolescents.

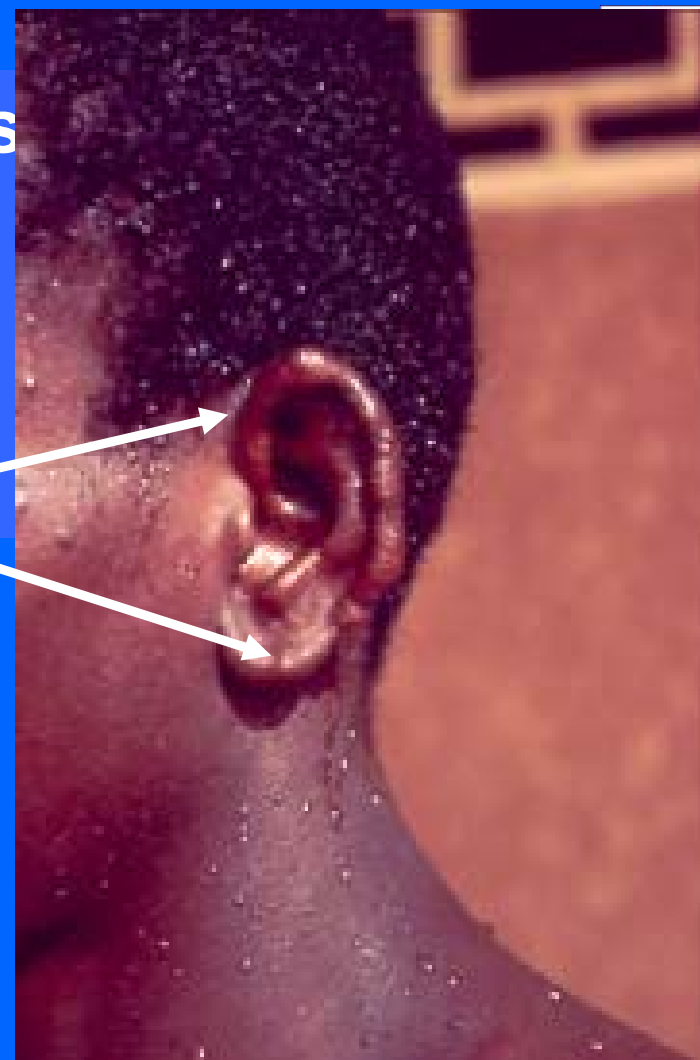

- ✓ Leprosy?
- ✓ PB or MB?
- ✓ Other diagnosis?

Answer: Acne vulgaris



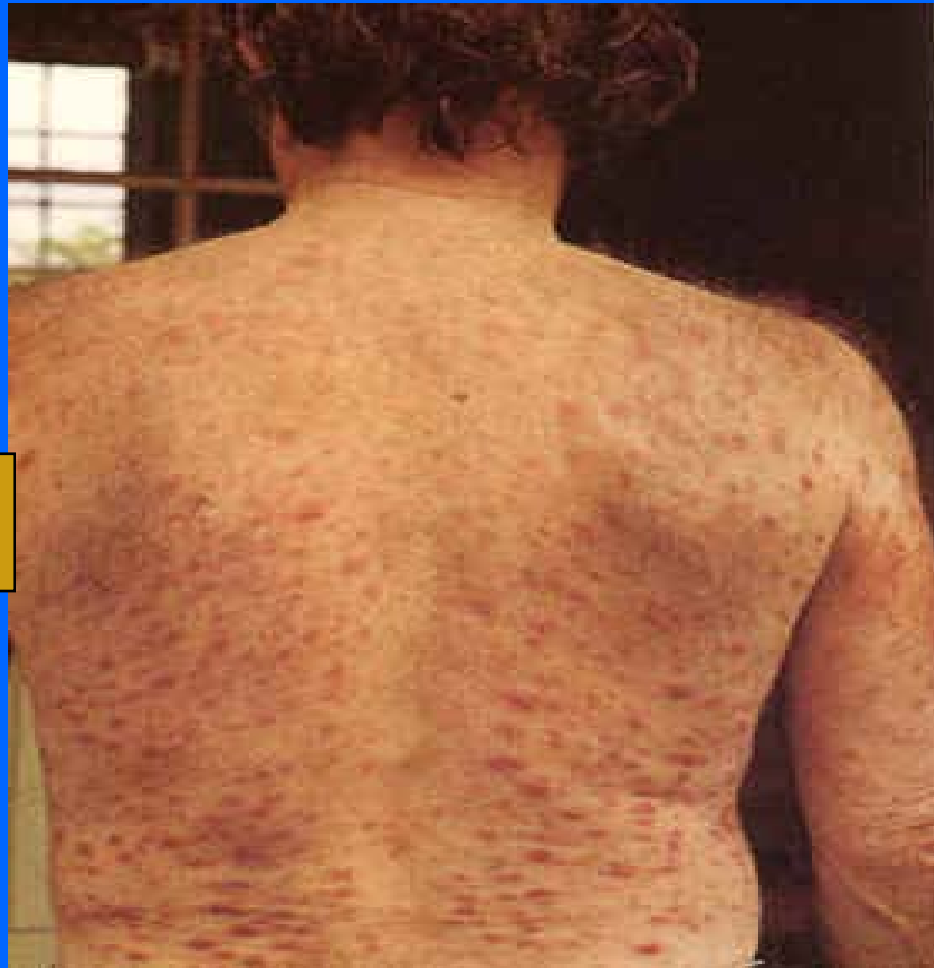**Raised lesions
(plaques and
nodules) on
the face and
ear-lobes**

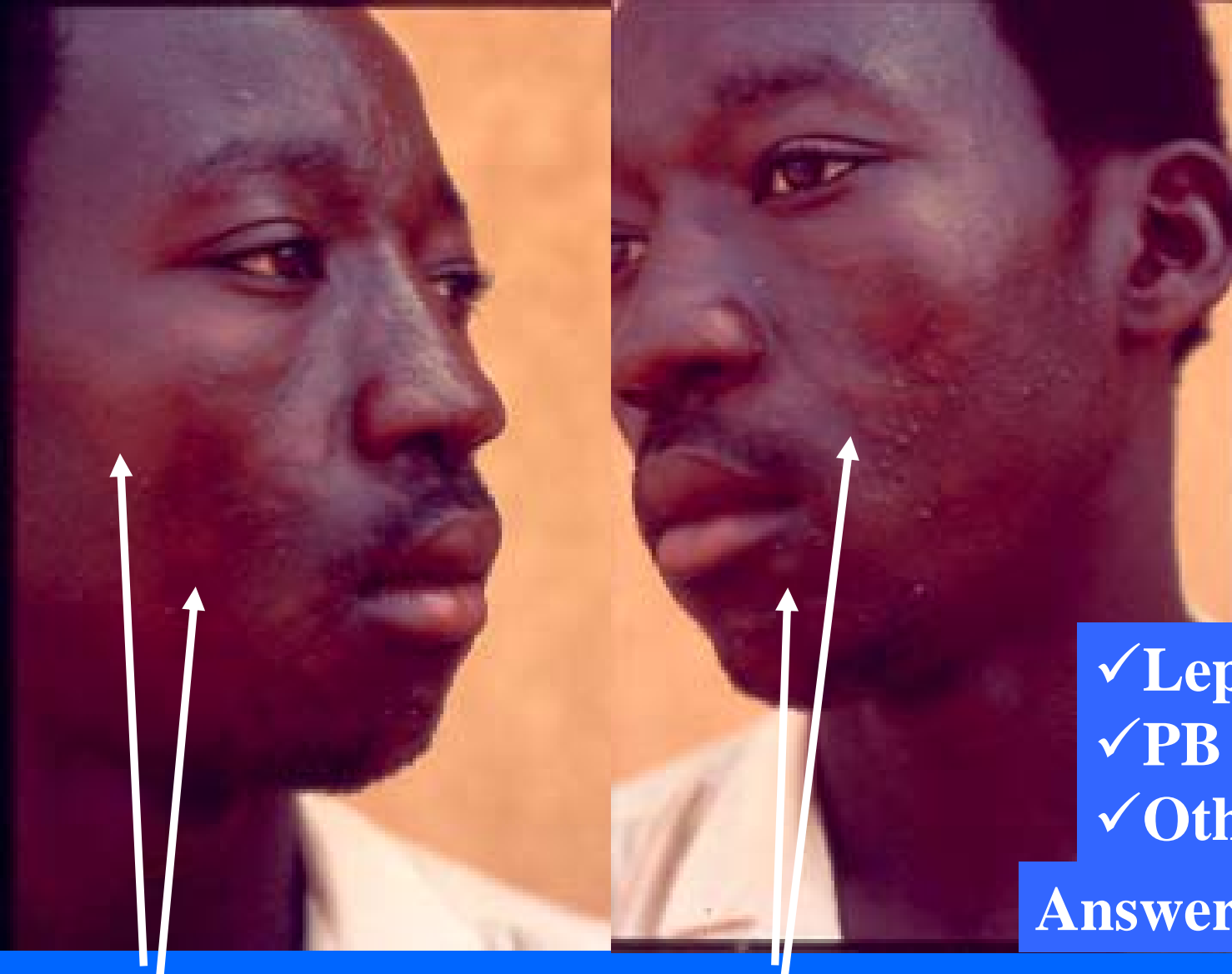

- ✓ Leprosy?
- ✓ PB or MB?
- ✓ Other diagnosis?

Answer: MB leprosy

Multibacillary leprosy
Pos skin smears

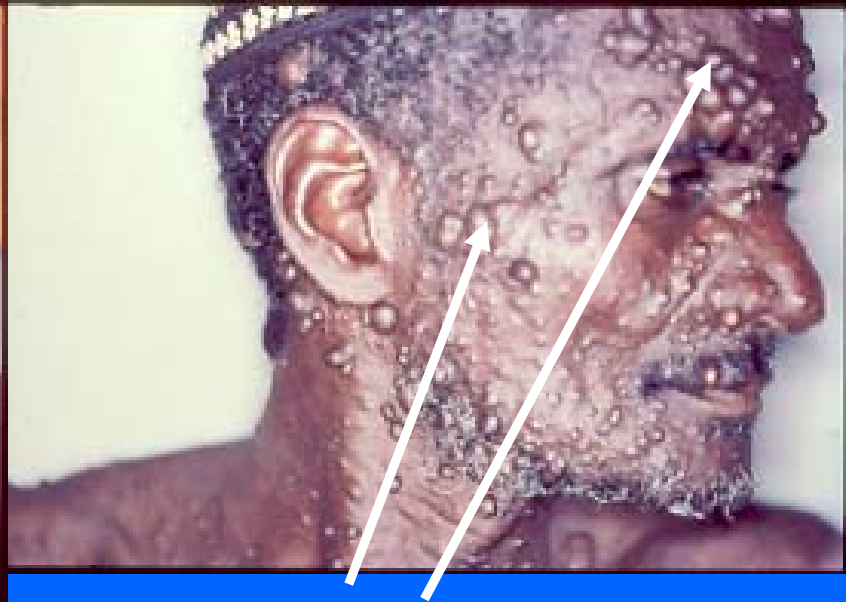
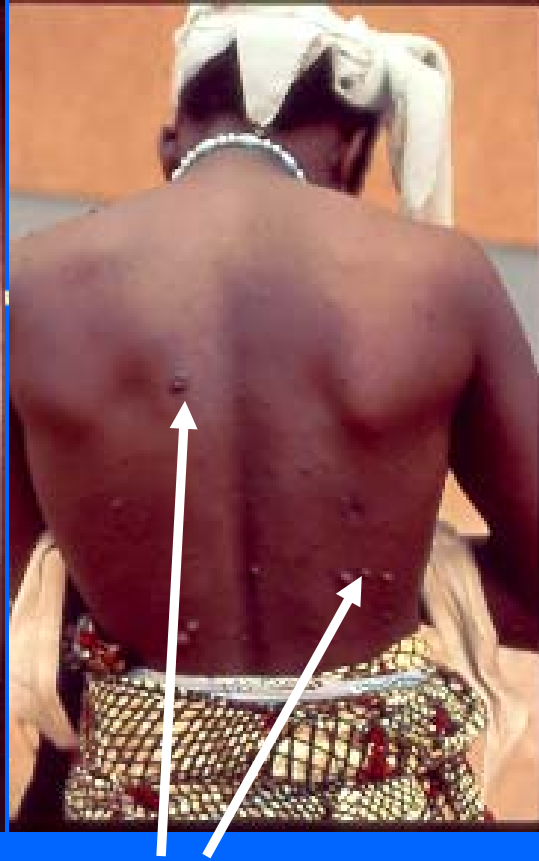
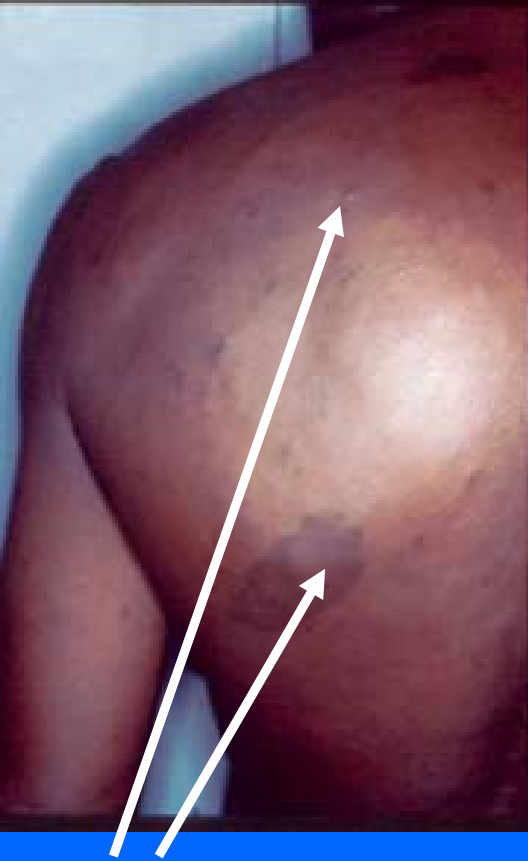

- ✓ Leprosy?
- ✓ PB or MB?
- ✓ Other diagnosis?

Answer: MB leprosy

Multiple clear lesions, patches and nodules on the face of a young man



**Severe form.
With tumours.**

**Early lesions
« cafe-au-lait »
macules**

**Moderate form with nodules, some
of which are umbilicated.**

- ✓ Leprosy?**
- ✓ PB or MB?**
- ✓ Other diagnosis?**


Answer:

Neurofibromatosis

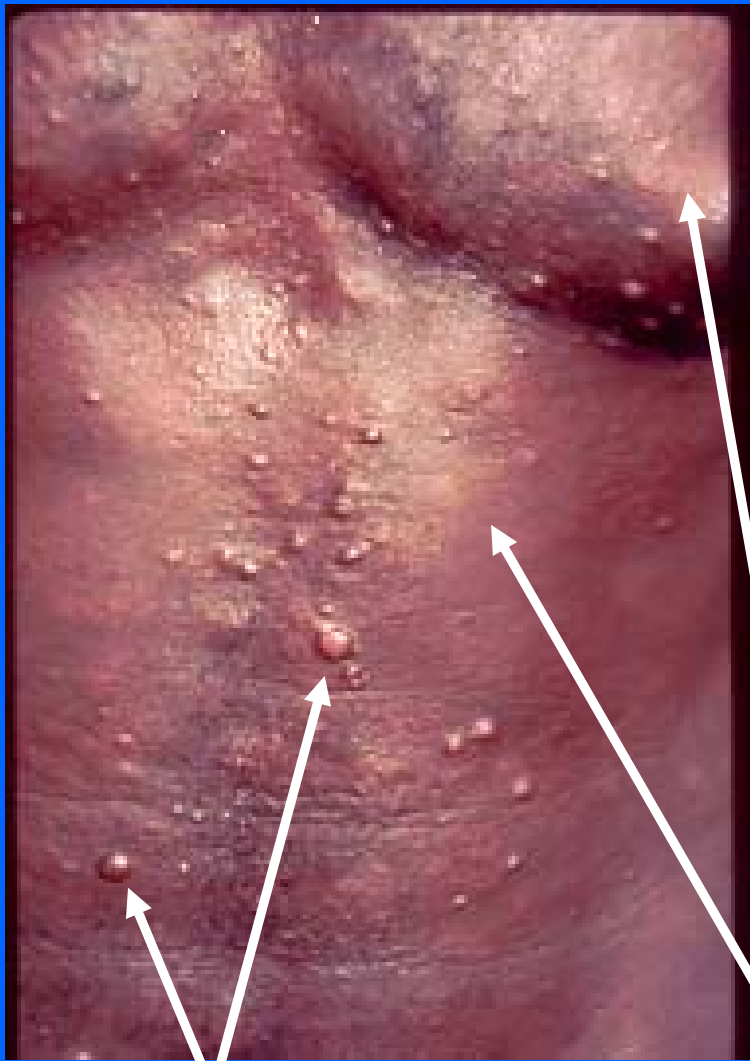

- ✓ Leprosy?
- ✓ PB or MB?
- ✓ Other diagnosis?

Answer: MB leprosy



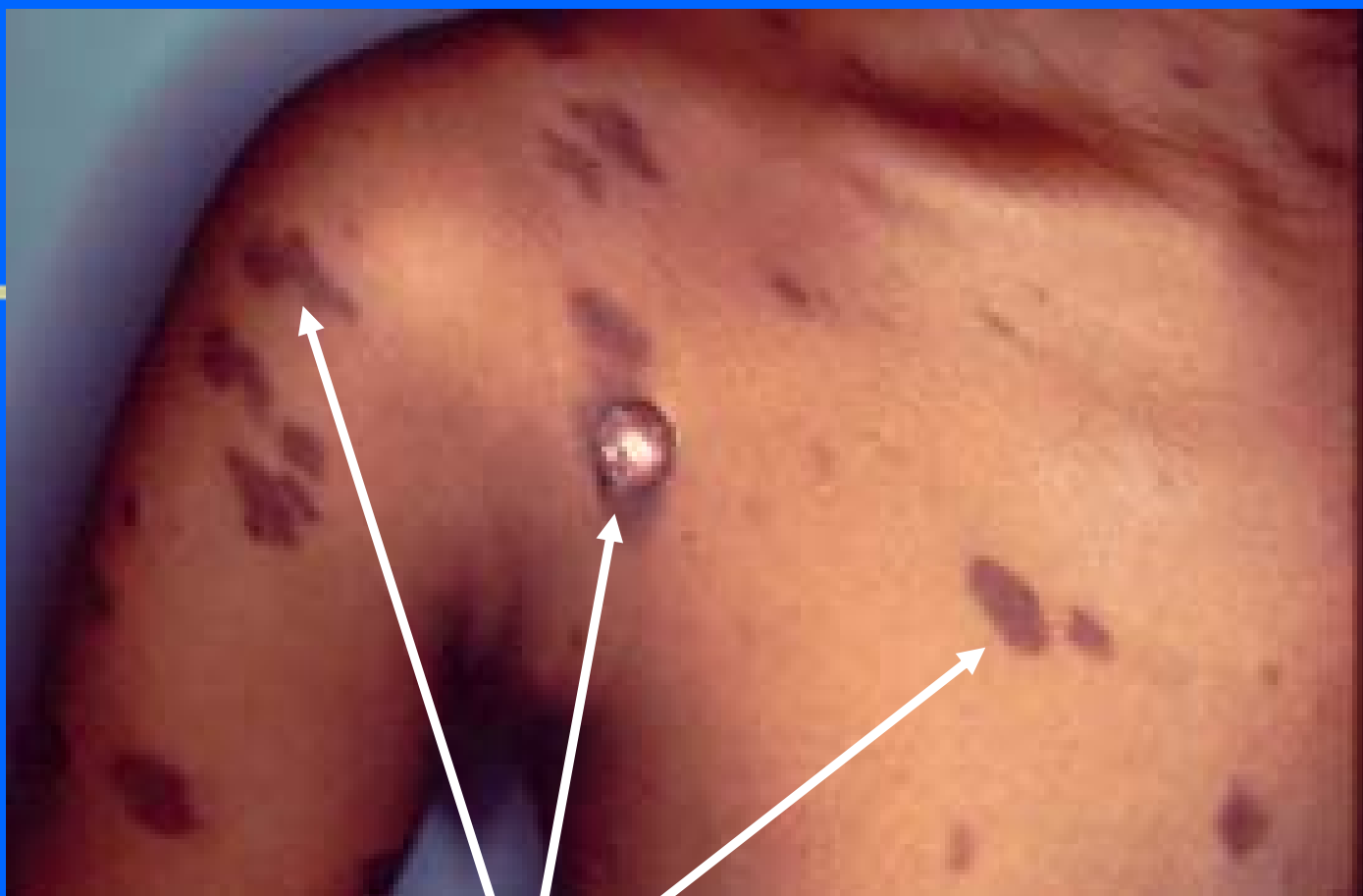Nodules on the face, lips and chin



- ✓ Leprosy?
- ✓ PB or MB?
- ✓ Other diagnosis?

Answer:
MB leprosy, histoid leprosy

Reddish nodules on infiltrated background



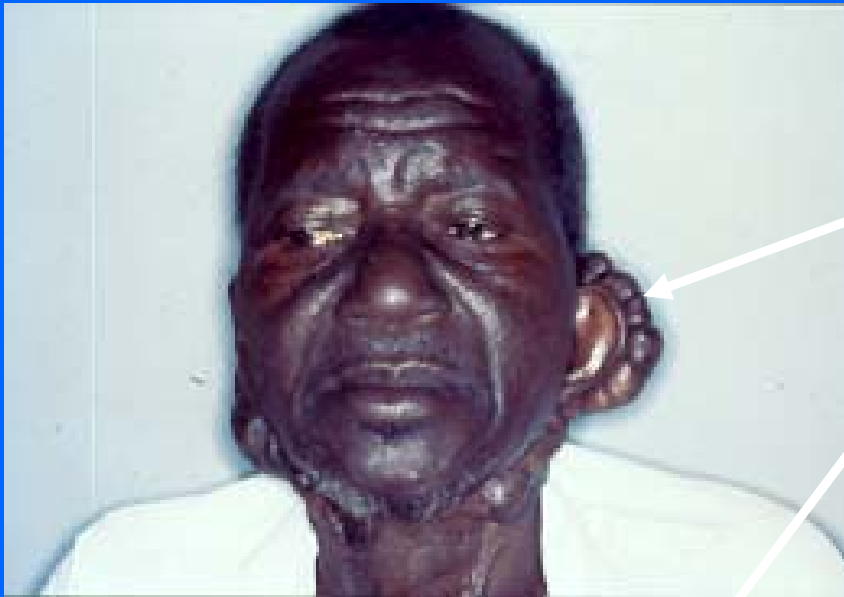Pigmented plaques and nodules

- ✓ Leprosy?
- ✓ PB or MB?
- ✓ Other diagnosis?

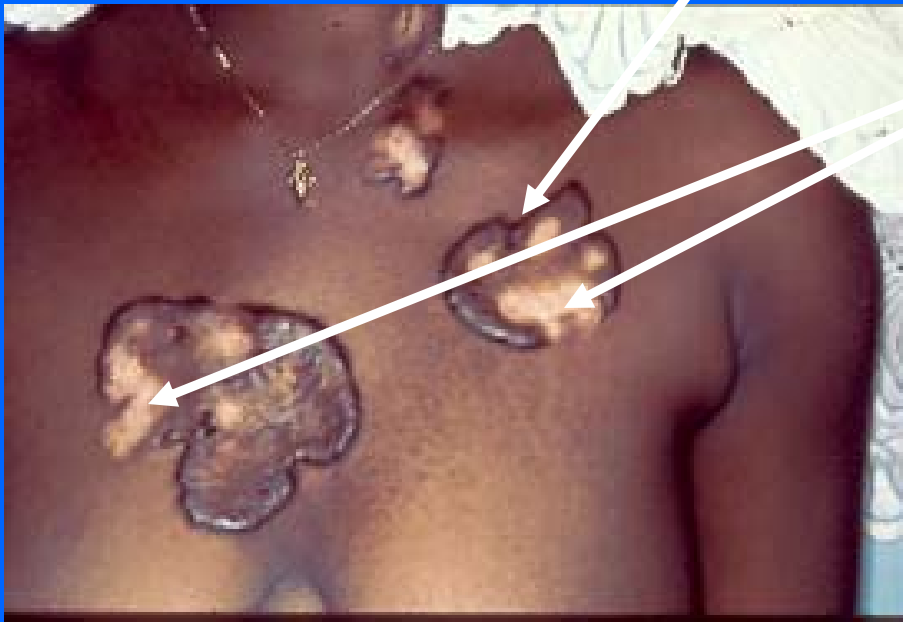Answer:
Kaposi's sarcoma



**Scar tissue following
trauma or
a skin infection**

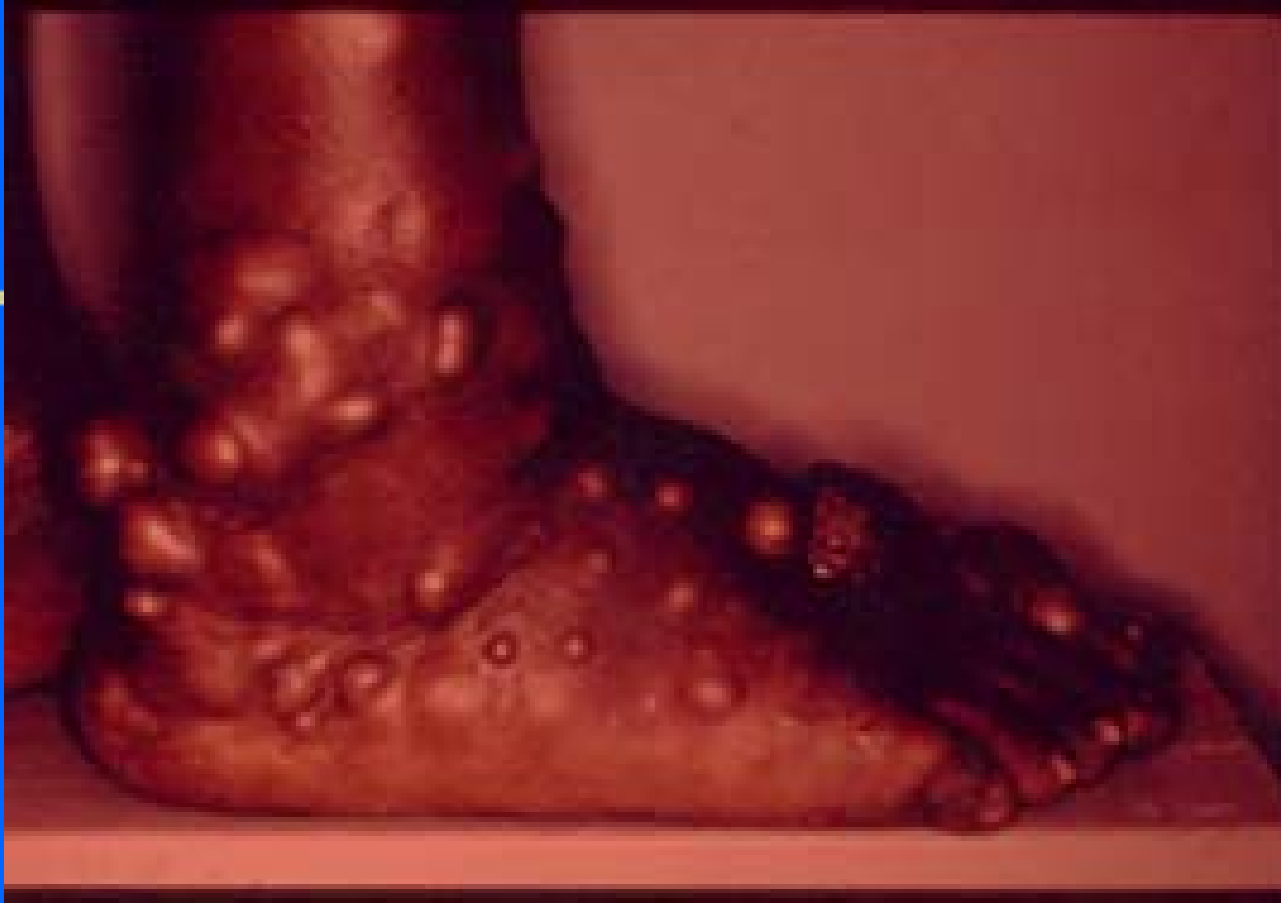

**Atrophy/depigmen-
tation followed
treatment with intra-
lesional corticosteroid
injections.**



- ✓ Leprosy?
- ✓ PB or MB?
- ✓ Other diagnosis?

**Answer:
Keloidal scars**



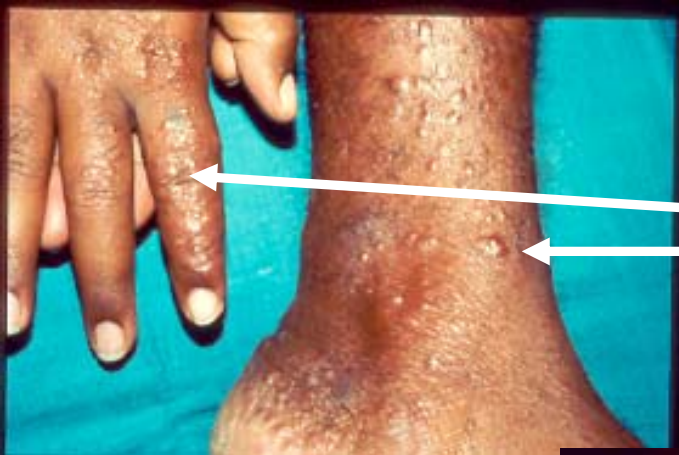✓ Leprosy?

✓ PB or MB?

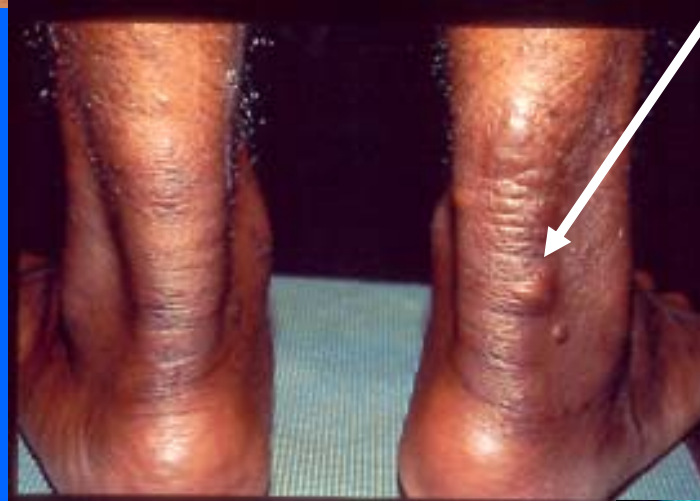✓ Other diagnosis?

Answer:

Nodules of Kaposi's sarcoma



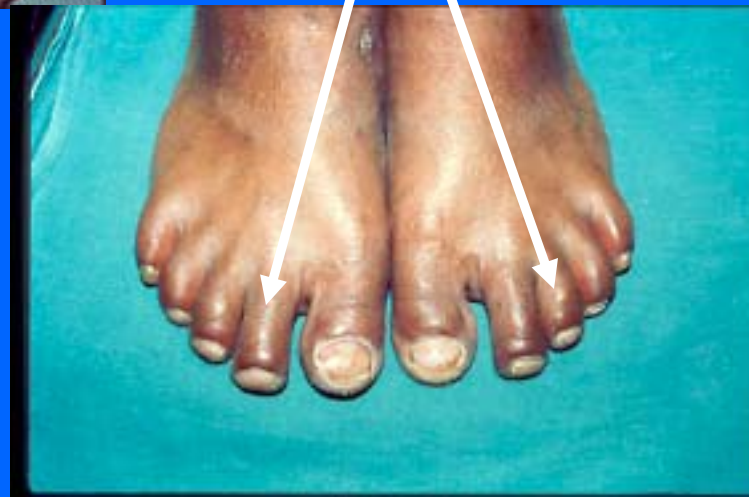Nodules on fingers, and lower legs

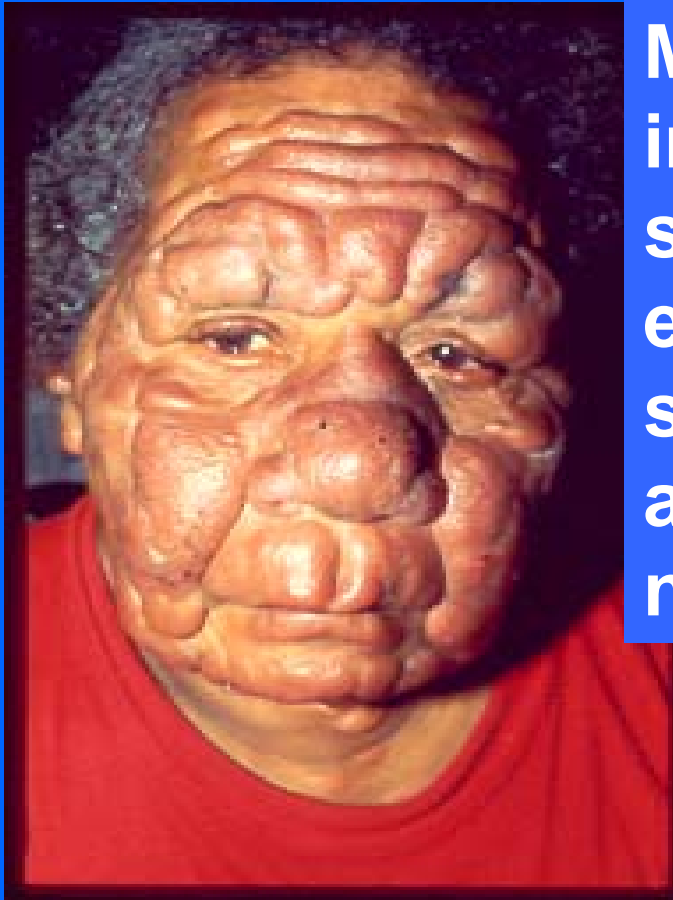

Oedema of the toes

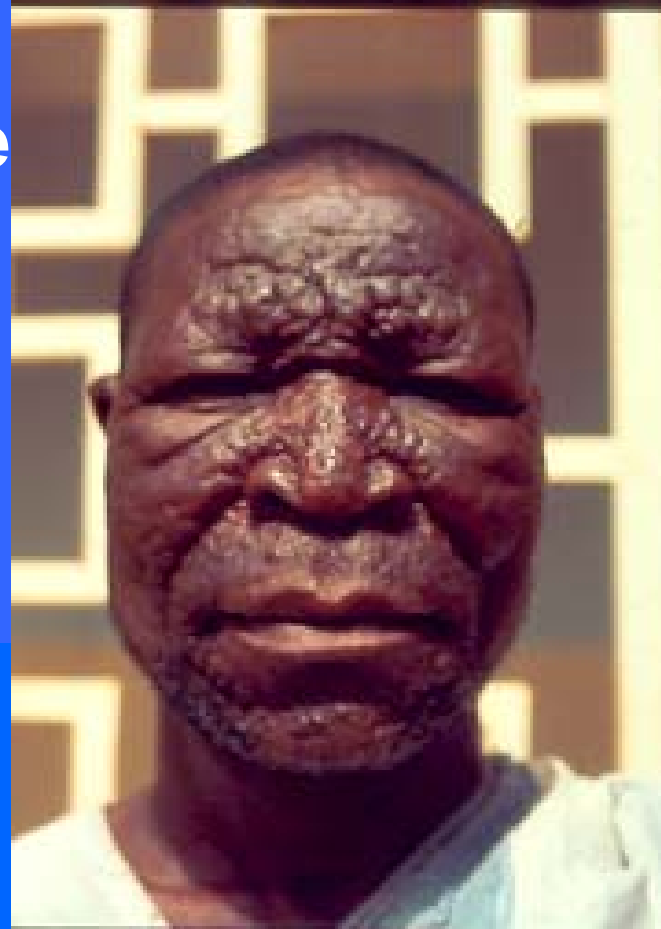- ✓ Leprosy?
- ✓ PB or MB?
- ✓ Other diagnosis?

Answer: MB Leprosy





Massive infiltration of the skin with exaggeration of skin markings and multiple nodules



- ✓ Leprosy?
- ✓ PB or MB?
- ✓ Other diagnosis?

Answer:
MB leprosy, « leonine » face



Thank you for your:

