

Management of Ulcers in Neurologically Impaired Feet in Leprosy Affected Persons

• H. SRINIVASAN

INTRODUCTION

If one is asked to visualise a 'typical leprosy patient', it is almost certain that the imagined figure will be a beggar, having a deformed hand – most probably crooked and shortened fingers – and a bandaged foot. This shows the extent leprosy is identified in the mind of the public with debilitation, deformity and ulcers. Despite the fact that hardly 10% of leprosy-affected persons have ulcers at any one time, one cannot imagine a leprosy patient without them. Of the two, deformities and ulcers, the latter, especially ulcers in the feet, are of the greatest importance because impaired mobility is a very serious 'handicap' for leading a normal life in society. In addition, frequent episodes of acute infection may interfere with work and smelling ulcers make the affected person an object fit for ostracisation. Ultimately, the patient may end up as a 'scarred' individual with mutilated or amputated feet, an object of pity dependent on others both physically and economically. Ulceration of the feet is the single most common cause of morbidity and debilitation of leprosy-affected persons. In view of this, it should be evident that any worthwhile leprosy project must have a planned programme for managing, i.e., treating and preventing, ulcers in leprosy-affected persons. The fact that most leprosy projects do not have such a programme only exposes their lopsided priorities, dictated more by preoccupation with 'public health' than concern for patients' welfare.

Different kinds of Ulcers

Leprosy-affected persons develop ulcers for a variety of reasons and the characteristics of the ulcers such as their location and clinical features vary accordingly. Broadly speaking, the ulcers may be classified into two groups, based on whether pre-existing nerve damage is a predisposing cause, as 'neuropathic' and 'non-neuropathic' ulcers. Unlike non-neuropathic ulcers, which may occur anywhere in the body, neuropathic ulcers occur only in sites having partial or total sensory nerve function deficit, which also come into physical contact with the external world. Neuropathic ulcers are thus mostly found on the soles of the feet. Accordingly, they can be classified as 'plantar' or 'extra-plantar' ulcers. Non-neuropathic ulcers may be "specific" or "non-specific" depending on whether ulceration was part of the disease process (Fig. 15-1). Of the different types of ulcers, neuropathic plantar ulcers are the most important clinically. They will be discussed in greater detail in this chapter.

Non-neuropathic Ulcers

The non-neuropathic ulcers group, as the name implies, are not due to nerve function impairment. They may be divided into specific or non-specific depending on the aetiology. Specific ulcers occur as part of the disease process and clinical picture of leprosy. Non-specific ulcers are not related to leprosy pathology. The non-specific ulcers in leprosy-affected persons are usually stasis ulcers.

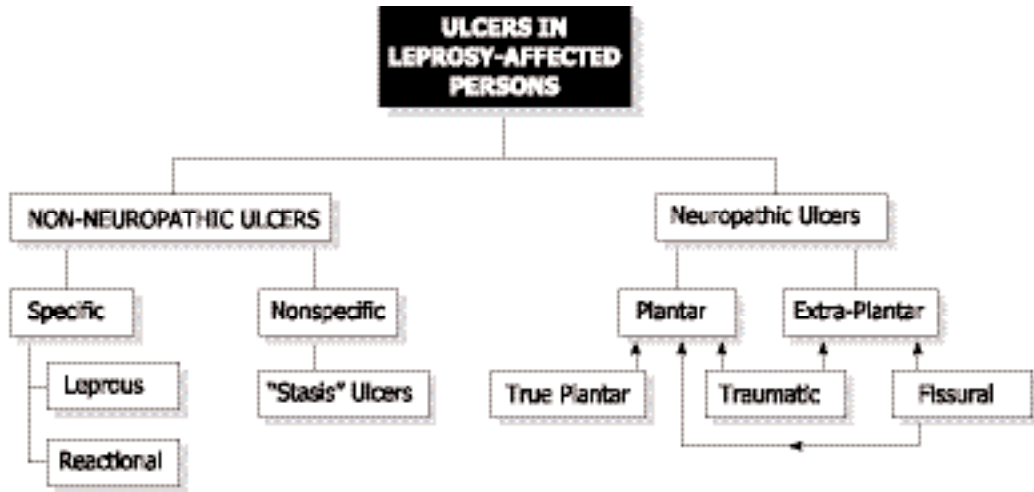


FIGURE 15.1 Ulcers in leprosy affected persons.

Specific Ulcers

Specific ulcers occur in the tissue background of leprosy pathology. Specific ulcers are of two types: leprosy or reactional. The former are seen in advanced cases of lepromatous leprosy while the latter are found in association with severe leprosy reaction, usually Erythema Nodosum Leprosum (ENL).

Leprosy ulcers occur because of skin breakdown over rapidly expanding lepromatous nodules. They are seen in patients with untreated, advanced, lepromatous leprosy. They are now uncommon indicating early case detection and good patient coverage under national leprosy programmes. Leprosy ulcers are found in sites of heavy infiltration and nodulation such as the face, elbows, dorsum of hands, and inside of the nose. The ulcers occur because the stretched skin over the nodule gives way exposing the leprosy granuloma underneath, which appears as pale granulation in the floor of the ulcer. The ulcer discharge is heavily laden with leprosy bacilli. These ulcers will heal rapidly once multidrug therapy is started. The ulcers need to be kept clean and covered with a bland dressing. There is no evidence to suggest that topical use of anti-leprosy drugs

like rifampicin or dapsone is necessary for healing these ulcers.

Reactional ulcers occur as part of the clinical picture of severe leprosy reaction, usually ENL but sometimes reversal reaction (RR). The ENL lesions develop into vesicles and pustules, or intense inflammation in coalesced ENL lesions or erythema multiforme-like lesions develop into large blisters that break open to expose large raw areas. In other cases of severe reaction, because of the intensity of inflammation, which in very severe cases may be compounded by arteriitis, there is tissue necrosis and breakdown, resulting in ulceration. Reactional ulcers are mainly seen on the extensor surfaces of the limbs and trunk. As they are part of the reactional process, aggressive treatment of the reaction with sufficiently high doses of steroids and adequate supportive therapy are needed for healing. Keeping the ulcer clean and covering them with a bland dressing is sufficient.

Like leprosy ulcers, reactional ulcers are usually superficial, often in the level of epidermis, with scarring only of the skin. Often the scars are hyperpigmented, occasionally vitiliginous. Ulcers on the fingers, especially over the proximal interphalangeal joints, may some-

times pose difficult therapeutic problems. In cases of severe reaction, there may be necrosis of the full thickness of the skin overlying the joint. In such cases, there is a great danger of the finger becoming stiff in a straight or flexed position. In such cases, the fingers need to be splinted in the functional position so that if they become stiff, they would still be of some use. Treatment of reactional ulcers involving the hand may pose problems to the therapist for, in order to achieve early resolution of inflammation the part needs to be rested, whereas the hand has to be kept mobile to prevent it becoming stiff. In severe cases, there is also a danger of necrosis of the tissue overlying the joint, due to associated arteriitis. That would expose the joint to secondary infection. These possibilities must be anticipated and treatment of high quality under the daily guidance of an experienced physiotherapist or technician is needed to prevent such outcomes.

Non-specific Ulcers

The most common chronic, non-neuropathic, non-specific ulcers are those similar in appearance to stasis ulcers. These ulcers are usually seen in middle aged or elderly persons, treated earlier for long-standing lepromatous leprosy. The ulcer, often located in front of the ankle and extending up the leg, is usually quite large. It occurs on the background of pachydermatous skin that may also exhibit varicose changes. The skin of the lower leg may be atrophic, thin and shiny. The ulcer frequently extends over the region of the medial or lateral malleolus. There is usually a history of some trivial injury preceding ulceration and the ulcer progressively enlarging instead of healing until it has attained the present large size.

The floor of the ulcer is sclerotic and covered with thin, pale granulation that may be easily scraped off without causing much bleeding. There is copious serous or sero-sanguinous discharge oozing from the ulcer, which is usu-

ally not positive for acid-fast bacilli. The bed of the ulcer is densely scarred and feels hard. A vitiliginous area indicating the past extent of ulceration often surrounds the ulcerated area. In their location, appearance and clinical behaviour these ulcers resemble the stasis ulcers seen in persons with incompetent venous valves or blocked lymphatics due to frequent attacks of lymphangitis and consequent blood or lymphatic stasis. No information is available in the published literature to show whether vascular or lymph stasis is actually present in these cases and, if so, their aetiology.

These ulcers are very refractory to treatment, healing is very tardy, tentative and often temporary. Skin grafts, even split-thickness grafts, often fail to take. Clinical experience suggests that keeping the ulcer clinically and bacteriologically clean and using occlusive, compression dressing coupled with exercises to improve drainage of blood and tissue fluid from the lower limb might assist healing. However, none of these treatments have been well studied.

NEUROPATHIC ULCERS

Neuropathic ulcers occur in a part of the body as sequelae of a pre-existing sensory deficit. These ulcers are found in those denervated parts of the body which come into contact with the external world. That happens because denervation has made the part vulnerable to the events and stresses that occur at that interface, initially at the time of their occurrence or subsequently. The foot is constantly in contact with the ground carrying the weight of the body in the course of its activities like walking and running. The soles of the feet are, therefore, the most frequent sites to develop neuropathic ulcers and these ulcers are known as '(neuropathic) plantar ulcers'. These ulcers cause maximum discomfort to the patients and in view of their importance they are discussed in some

detail below. Ulcers occurring in other denervated sites, such as the dorsum and lateral malleolar region of the foot and the hands are described under '(neuropathic) extra-plantar ulcers'. Neuropathic plantar ulcers are usually referred to simply as 'plantar ulcers'. They are also commonly known as 'trophic ulcers' and less commonly as 'perforating ulcers', 'penetrating ulcers', or 'mal perforans'.

Concepts of Causation of Plantar Ulcers: A Historical Review

It is worth recapitulating briefly the evolution of our concepts of the causation of plantar ulcers since all of them still persist to a varying extent, among the affected persons and health workers alike, thereby impacting treatment and outcome, sometimes adversely.

Leprosy is the cause

Till about the last decade of the 19th century it was the general belief that leprosy "devitalized" tissues, depriving them of their ability to survive and withstand stresses. It was believed that tissues rotted and dropped off (e.g., shortening of fingers and toes). The additional stress of carrying the body weight and the resulting pressure caused the "devitalized" bones and other tissues of the foot to undergo necrosis. Ulceration was seen as the means by which the body attempted to get rid of the dead tissue. Finding pieces of dead bone in the depths of these ulcers coupled with the observation that removal of those pieces and resting the foot usually healed the ulcer were considered as providing proof of this view.¹⁷ Thus, leprosy was considered to be directly responsible for these ulcers. For that reason, these ulcers were considered highly infectious and thought to be a serious way the disease spread in the community. Many lay people and even some leprosy workers still subscribe to this view. Hence, the advocacy and use of topical anti-leprosy drugs, ranging from hydnocarpus oil to

rifampicin, by some people even today for healing these ulcers.

Neuropathy is the cause

By the last few decades of the 19th century it had been established that the nervous system controlled the functioning of most if not all of the organs of the body. It was then postulated that there ought to be 'trophic' nerves that regulated cell metabolism in order to maintain the integrity of cells and tissues against 'wear and tear'. In patients with leprosy and other neuropathies it was presumed that the 'trophic nerves' would also be damaged in due course, and that this would cause 'devitalization' of cells, tissues and organs. Thus denervation and particularly damage to the hypothetical "trophic nerves" was presumed to be the primary cause of 'devitalization' of tissues which then broke down under conditions of normal use or abnormal stress. These ulcers were therefore called 'trophic ulcers', a term that is still in use widely.

Trauma is the cause

According to this line of thinking unperceived injuries to the foot and neglect of those injuries were considered to lead to the formation and maintenance of ulcers. Both lack of perception of the injury initially and neglect of the injured part subsequently were explained as being due to insensitivity and consequent lack of feeling of pain, because of damage to the peripheral nerves. The fact that these ulcers always occurred in feet with loss of protective sensation, and the not infrequent finding in their depths of foreign bodies like stones, were taken as proof for this view. This situation continued till the middle of the 20th century.

Ischemia is the cause

Around 1950, Paul Brand and a band of young orthopaedic surgeons under his leadership

started taking interest in the problems of leprosy-affected persons. They were struck by the fact that there was great damage to deeper tissues and that the ulcers occurred almost exclusively in the weight-bearing areas. This suggested that these ulcers might be pressure sores, somewhat like bedsores. Simple measurements, of the area of weight-bearing surface and the load on that area, assuming that 50% of the weight was borne by the heel and the other 50% by the ball of the foot, showed very clearly that pressures in the sole during standing would far exceed the blood pressure, blocking entry of blood to the compressed part of the sole. It was evident that continued standing without relieving the sole of the foot, by frequent shifting of weight from one foot to the other, would cause severe ischemia. That would be sufficient to lead to ischemic necrosis of the subcutaneous tissue and then of the overlying skin causing ulceration. Persons with insensitive feet would not feel the ischemic pain and so (it was postulated) would not shift the weight from their feet periodically as healthy individuals do, thus allowing development of ulcers. On this basis patients were instructed not to stand for 'prolonged periods'.¹³

While the logic of this hypothesis was sound, the basic premise that one could stand for "prolonged" periods (for four to five hours or longer! - which is what "prolonged" means in the present context) without swaying, continuously loading the sole, was not realistic for two reasons. Firstly, people rarely, if ever, stand like that.⁷ Secondly, the body cannot stand still even for a few seconds, as the living body is constantly swaying, mostly forwards and backwards, as the muscles are constantly pulling the body in one direction or the other to prevent it from falling. Thus, standing is an act of dynamic equilibrium and one cannot stand 'absolutely still' even for a minute, let alone for the hours required to produce ischemic necrosis and ulceration of the sole.

Walking is the cause

Price, a surgeon working in Nigeria, published in 1959 three papers on plantar ulcers in leprosy which gave us a new insight into the causation of ulcers.³³⁻³⁵ It was Price who introduced the term 'plantar ulcer', instead of the then popular 'trophic ulcer'. Price made three important observations:

a) The ulcers were not randomly distributed in the weight-bearing area of the sole; instead, there was a bias for the ulcers to be located under the metatarsal heads. About 70% of the ulcers occurred in this part of the sole, with 10% occurring in the heel, and a further 10% in the midlateral part of the sole. The risk of ulceration of the forepart of the sole of the foot was therefore about seven times greater than that of the heel. This pattern of preferential ulceration of the ball of the foot was confirmed soon after in South India, at Karigiri and Chingleput (Fig. 15-2).^{41,44}

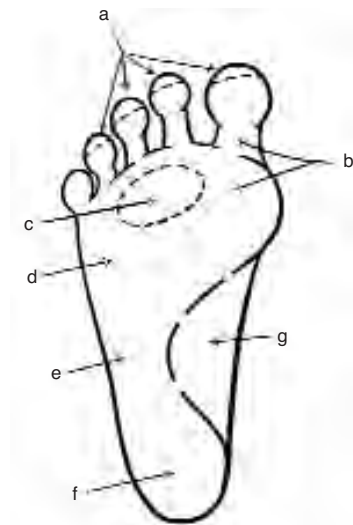


FIGURE 15-2 Frequency of distribution of ulcers in sole of the foot a) tips of toes <5%; b) big toe region 30-50%; c) central toe region; 2nd-5th metatarsal heads 20-30%; d) Metatarsal head region 15-20%; e) mid lateral border of the foot (base of 5th metatarsal) 15-20%; f) heel 5-10%; g) instep <1%.

b) The ulcers started as blisters over areas of necrosis. There was an initial area of deep inflammation followed by necrosis of the subcutaneous tissue, which was followed by the development of the 'necrosis blister'. While the blister usually lay over the area of necrosis, the blister fluid sometimes tracked along paths of 'least resistance' and surfaced at a distance.

c) The ulcers developed in one of three ways:

1. through infection of a (usually penetrating) wound giving rise to a traumatic ulcer;
2. through infection of a deep skin crack, frequently found in the anhidrotic soles of these patients, or, infection of a 'bursa' deep to a callosity/corn through a fine crack giving rise to a fissural ulcer or,
3. more commonly, because of the stresses and strains on the tissues of the sole during walking giving rise to a 'true' plantar ulcer. Price pointed out that the stresses and strains of walking lead to ulceration and that this explains the special vulnerability of the ball of the foot for ulceration. According to Price, only the last type of ulcers would qualify to be called 'plantar ulcers'. However, it is common experience that these ulcers, once they have developed, behave the same way and have to be managed the same way irrespective of their initial cause, be it trauma, fissure or walking. Probably for this reason and also because patients are rarely seen at the initial stage, no distinction is now made between 'true' and other types of plantar ulcers and all are referred to simply as 'plantar ulcers'.

Price did not, however, explain why walking strains should cause ulceration in insensitive feet only. Brand has advocated the idea that leprosy patients with insensitive feet walked 'excessively'. He has shown experimentally that even a small rise in stress when

repeated innumerable times causes aseptic inflammation at that site and that the inflamed sites then break down easily.⁶ Patients were, therefore, advised not to walk 'too much' and to rest their feet at periodic intervals if they had to walk 'long distances'. Srinivasan found that a history of prolonged walking preceded the initial development of ulcers in only a few cases. His study showed that insensitivity of the sole introduced a risk of ulceration (ca. 6% in his patients) and that the risk increased (12-72%) when there was associated paralysis of the plantar intrinsic muscles.⁴⁵ This study further showed that paralysis of muscles or muscle groups rendered particular sites more vulnerable.

That observation would further support the thesis that paralysis of the plantar intrinsic muscles increases the risk of ulceration in the ball of the foot.

Current View of Causation of Plantar Ulcers (Fig. 15-3)

The currently held view is as follows. A minority of ulcers (ca. 10%) arise from perceived or unperceived injuries with neglect of these injuries resulting in infection and tissue damage. Another small proportion (ca. 5 %) arise from neglect of deep cracks in the dry (anhidrotic) and hyperkeratotic skin of the sole, or, from infection of 'bursae' underlying callosities or corns, through fine cracks. The majority of plantar ulcers arise from breakdown of plantar subcutaneous tissue due to the stresses and strains of normal walking.

All plantar intrinsic muscles exert their effect in the region of the metatarso-phalangeal joints. When these muscles are paralysed, the compression and shearing forces are increased, even during normal walking. The plantar intrinsic muscles are maximally active during the "push off" stage of walking when the fore part of the foot pushes the ground backward in

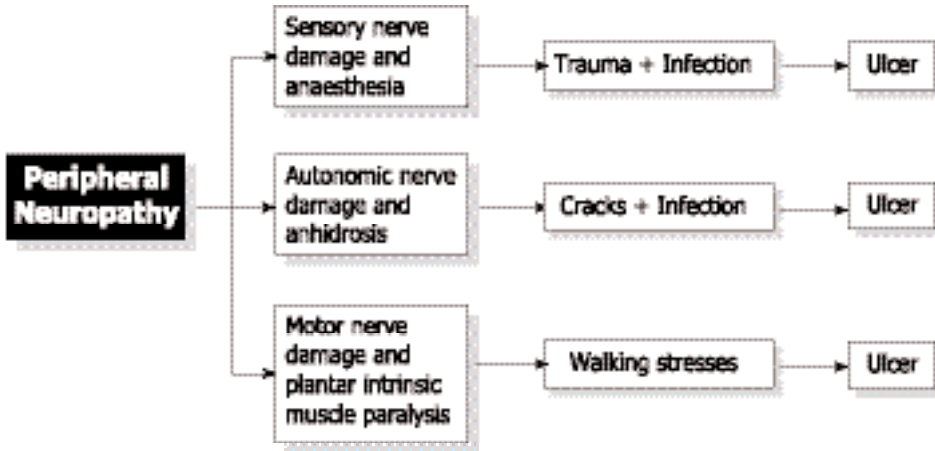


FIGURE 15-3 Current concept of plantar ulceration.

order to propel the body forward.¹ Their contraction creates a thrust that will counter the compressive, shearing and distracting forces at the metatarso-phalangeal joint region that are normally generated at this stage of walking. When the plantar intrinsic muscles are paralysed, this protective effect is lost, and the toes get clawed during the “push off ” stage of walking, causing momentary increases in stresses and strains in the region of the metatarso-phalangeal joint at each step. Brand has shown that even small increases in stresses

can lead to breakdown of tissue if repeated long enough, causing ulceration.⁶ Similarly, paralysis of long muscles also increases the risk of ulceration at specific sites due to momentary increases in stresses at those sites as shown below (Fig. 15-4).

Other causes of plantar ulceration

While most plantar ulcers arise in the manner described above, other (known or not yet known) causes may be operating occasionally

Muscle Group Paralysed	Site Made Vulnerable
Plantar intrinsics	Ball of the foot
Abd. hallucis group	I Metatarsal head region
Interossei-lumbricals	II, III, & IV Metatarsal head region
Abd. dig. minimi group	V Metatarsal head region
Fl. dig.brevis / interossei & lumbricals	Tips of toes
Foot dorsiflexors	Heel
Peronei (evertors)	Head / Base of V metatarsal
Calf muscles (plantar flexors)	Heel

FIGURE 15-4 Sites rendered vulnerable to ulceration by particular muscle paralysis.*

* The reader is advised to also study chapter 12 for additional insights into the pathogenesis of plantar ulceration (eds.).

to give rise to an ulcer. Thus obvious or occult anatomical anomalies and variations, improper or ill-fitting footwear, vascular insufficiency or rare fungal or bacterial infections may lead to ulceration of different parts of the foot. These factors, however, usually determine the site of an ulcer rather than initiate one.

STAGES OF ULCERATION

The pathogenesis of plantar ulcers may be described in terms of three 'stages' namely the stage of 'threatened' ulcer, the stage of 'concealed' ulcer and the final stage of 'overt' or open ulcer.

Stage of threatened ulcer

In terms of pathology, this stage may be called "pre-ulcerative stage of aseptic inflammation". Increased stress repeated over a period of time gives rise to a focus of traumatic (aseptic) inflammation in the region of the subcutaneous layer of the sole of the foot, which is most vulnerable to mechanical stress. This occurs at the site of increased stress, usually under a joint or a bony prominence, very often just distal to the head of a metatarsal. The affected site is oedematous. This is seen as mild or obvious splaying of a toe, which stands apart from its neighbour to a greater or lesser extent.³³⁻³⁵ The affected site is often tender to deep digital pressure. Clinicians do not often get to see feet in this stage since patients rarely report at this stage.

Stage of concealed ulceration

This is the stage of "necrosis blister". The inflamed site undergoes necrosis on continued subjection to stress, by walking, with the subcutaneous tissue undergoing colliquative necrosis. The liquefied tissue mixed with some blood is forced to the surface by continued walking to present as a blister. This is the so-called 'necrosis blister'. This blister usually directly overlies the area of necrosis, but some-

times, when the overlying tissue is too tough, it may track along a path of least resistance and emerge to the surface at a distance, at the side of the toe or in the interdigital web.³³⁻³⁵ This stage also often goes unnoticed. Even when noticed, patients may mislead the physician by attributing the blister to (an unperceived) burn as, in their experience, burns cause blisters (Fig. 15-5). Only close questioning will reveal that 'the burn' was an assumption or an inference and not a fact or direct observation.

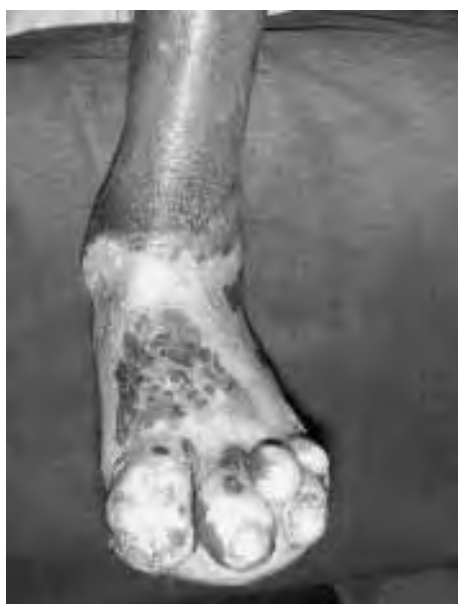

FIGURE 15-5 Burn in a newly diagnosed leprosy patient; patient presented with the burn.

Stage of overt ulceration

With the formation of the necrosis blister the essential process of ulcer formation namely, destruction of the subcutaneous tissue, is complete except that the "ulcer" is not seen or obvious as it is still covered with skin. When the skin overlying the blister breaks open, the ulcer site becomes exteriorised, the necrotic area becomes exposed to the external world and there is an obvious ulcer.

PROGRESSION OF PLANTAR ULCER

An ulcer does not usually bother the patient except for its nuisance, as there is usually no accompanying pain. It may enlarge to some extent and continue like that, without healing, for some weeks or a few months. Sooner or later it can become acutely infected with 'street organisms' like *Staph. aureus*, *E. coli*, or *B. proteus*.^{9,11,14,31} The part becomes swollen, the oedema showing up prominently over the dorsum even when the infected site is in the sole, and the edges of the ulcer are also swollen. There is copious discharge of pus or sero-sanious fluid, which may be foul smelling. The floor of the ulcer is often covered with necrotic tissue. There may be associated groin adenitis, lymphangitis and fever, depending on the severity and extent of localization of infection. Examination of the blood shows polymorphonuclear leukocytosis. The ulcer presenting in this fashion, with acute inflammation, is often referred to as an 'acute ulcer'. Initially, the infection and inflammation are confined to the subcutaneous tissue and plane, without it extending to deeper tissue or structures like bones, joints or tendon sheaths. In that case

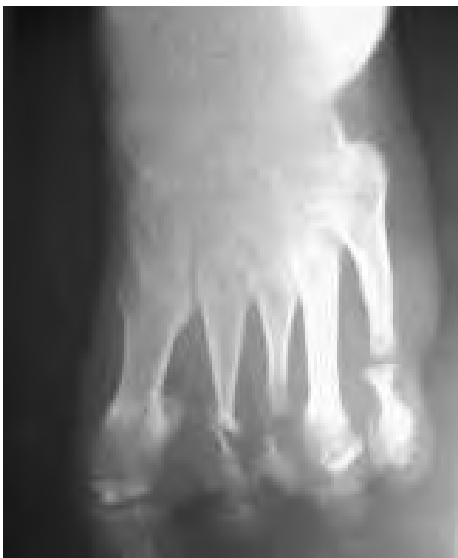

FIGURE 15-6 Early digit/metatarsal bone loss secondary to ulceration.

they are also called 'simple ulcers' or 'uncomplicated ulcers'. Usually, the patient seeks relief at the stage of acute inflammation and with treatment the inflammation subsides, and the ulcer may also heal. Or, after improving for some time, the ulcer may remain unchanged and continues to be present as a small raw area. The acute ulcer has become quiescent and has entered the chronic stage. From now on it is referred to as a 'chronic ulcer'.

The chronic ulcer, as the name suggests, remains unchanged and unhealed for some time and then may flare up again as an acute ulcer. With treatment the acute inflammation subsides and the ulcer reverts to the chronic status once more. Over the course of years, this cycle (chronic ulcer → acute ulcer → chronic ulcer) may be repeated (Figs. 15-6,7). During any one of the acute episodes the infection may break through the natural barriers and extend to one or more deeper structures such as an underlying joint or bone or an adjacent tendon sheath or, a 'plantar space'. Ulcers in the midlateral border of the foot are dangerously close to cubo-metatarsal and calcaneo-cuboid joints to which infection may easily spread and from there to the other tarsal joints. Such extension of infection to deeper structures converts the 'simple ulcer' into a 'complicated ulcer'. In this

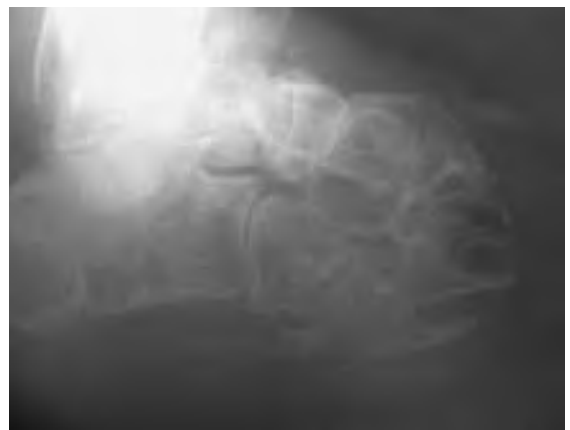

FIGURE 15-7 Advanced bone loss secondary to ulceration.

manner, the plantar ulcer may result in additional complications like osteomyelitis, septic arthritis or tenosynovitis. These complications may result in fixed deformities of toes or foot, loss of bone and flail or disorganised joints. It is not anymore a plantar ulcer, but a sinus with deep ramifications associated with profound structural changes in the foot, with corresponding functional consequences. The term 'penetrating ulcer' is sometimes used to refer to an ulcer that extends deeply into a tarsal bone, like the calcaneus. Sometimes, the sinus finds its way through the full thickness of the foot and opens out in the dorsum of the foot. Such an ulcer, which perforates the foot through and through, is called a '*perforating ulcer*' or *mal perforans*. Severe and repeated infection causes extensive tissue necrosis with replacement of the dead tissue with scar tissue. Scar tissue cannot withstand the stresses and strains generated in the foot during walking and, sooner or later it may break down and the ulcer that healed with great difficulty breaks open readily. These ulcers, which recur readily, with little provocation and despite taking proper care and adequate protective precautions including the use of appropriate footwear, are referred to as 'recurrent ulcers' in which the recurrence of the ulcer itself is the main complication.

CONSEQUENCES OF REPEATED ULCERATION

Each episode of recurrent ulceration is associated with additional tissue damage and further scarring at the site making the part more vulnerable to ulceration. Further, soft tissue loss, scar contraction, pathological fractures and bone loss associated with chronic osteomyelitis, and destruction of an underlying joint often cause development of fixed deformities, abnormal bony prominences and functional abnormalities. During walking and even during standing, these abnormalities can cause

increased pressures and other stresses and strains on the already vulnerable scar leading to the breakdown of the scar even more readily. A vicious spiral is set up in this manner leading to progressive and extensive destruction and mutilation of the foot. The plantar ulcer may rarely develop some other complications such as life-threatening clostridial infections (tetanus, gas gangrene), or, septicæmia. Occasionally, long standing ulcers may undergo malignant or premalignant degeneration developing into a 'cauliflower growth' that may be squamous-cell carcinoma or identical-looking pseudo-epitheliomatous hyperplasia.⁴⁹ The natural history of plantar ulcers is shown in Fig. 15-8.

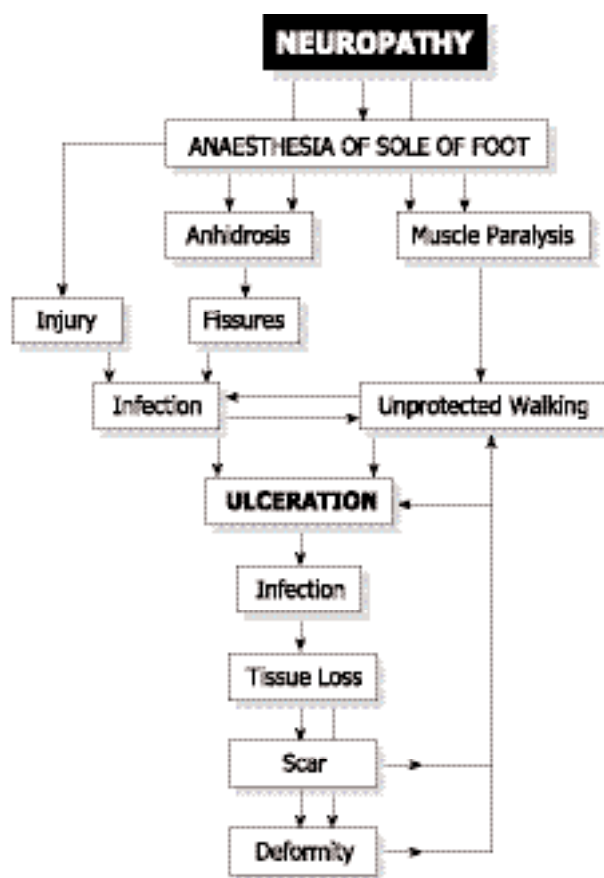


FIGURE 15-8 Natural history of plantar ulceration.

LOCATION OF PLANTAR ULCERS

As pointed out by Price, plantar ulcers are not distributed randomly in the sole of the foot, but are found more often at some sites than others. Thus, the forefoot is the most favoured site, accounting for 70% to 80% of the ulcers. Srinivasan showed that even in the ball of the foot, the frequency of ulceration progressively increased from the lateral to the medial part, the first metatarsal head region being the most common site (Figs. 15-2 and 9).⁴⁶ Ulcers are least common in the region of the medial arch (instep) of the foot. The frequency of ulceration increases progressively in the following order: tips of one or more toes, pulps of one or more toes, heel, mid lateral border of the foot (base of 5th metatarsal), region of the 5th metatarsophalangeal (MTP) joint, region of central three MTP joints and the region of the MTP joint of the big toe being the most common sites. Although the last three sites are commonly referred to as being 'under a metatarsal head' (MTH region), the ulcer is usually located just distal to and not right under the metatarsal head. The toes are webbed to a much greater extent than the fingers and the metatarsal heads are not located as far forward in the ball of the foot as commonly imagined. The exact location of an ulcer is determined by a number of factors. A traumatic ulcer may occur any-

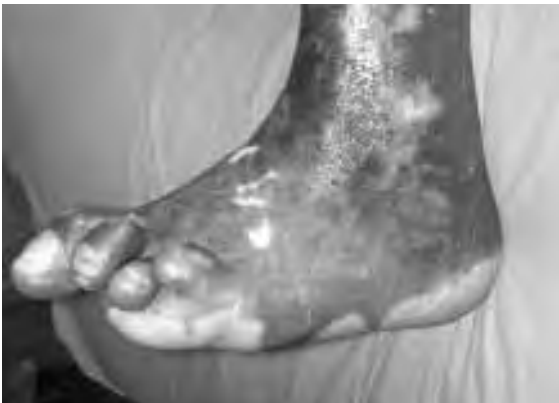

FIGURE 15-9 Forefoot deformity secondary to plantar ulceration.

where in the sole of the foot, since a thorn, nail, or a sharp stone will penetrate any part of the foot with which it comes into contact. Fissures, and fissural ulcers, on the other hand, occur around the margin of weight-bearing areas in the sole.

NEUROPATHIC EXTRA-PLANTAR ULCERS

Extra-Plantar Foot Ulcers

Neuropathic ulcers may also be found in sites other than the sole of the foot. These are known as extra-plantar ulcers. Thus in the foot, extra-plantar neuropathic ulcers are seen on the dorsum or over the lateral malleolus. The ulcers over the dorsum of the toes are due to rubbing of the toe (usually the second toe) by an ill-fitting strap of the sandal or the upper of the shoe. In these cases, the toe is usually deformed, having a fixed or mobile claw deformity. Sometimes, a flail little toe develops ulceration over its dorsum, again due to frictional trauma from the shoe or sandal.

Ulcers over the lateral malleolus arise from pressure and friction due to cross-legged sitting. The tissues over the lateral malleolus get caught between the ground and the underlying bone. Repeated and continuous compression causes the skin over the lateral malleolus to be thickened and hyperkeratotic and a corn develops in that area. The corn increases the compression and shear stresses, causing an adventitious bursa to develop between the corn and the underlying lateral malleolus. The bursa becomes chronically inflamed with thickening of its walls, because of repeated trauma from sitting. At some stage, fine cracks develop in the skin overlying the bursa. The bursa may get infected, a collar stud abscess develops, bursts open discharging pus leaving behind a chronic sinus communicating with the infected bursa underneath. The skin overlying the infected bursa may slough off and a large indolent ulcer

extending over the entire lateral malleolar area develops. If not treated properly and promptly the bone may also become involved. With continued neglect, the infection may spread further to involve the ankle joint with disastrous consequences. Instances are not unknown in which the entire talus had been extruded as a sequestrum in cases of sepsis of the ankle.

Extra-Plantar Hand Ulcers

Neuropathic ulcers occur also in the hand. In fact, hand ulcers are at least as common as plantar ulcers but they usually heal quicker as, unlike the feet, wound healing in the hands is not complicated by having to bear the weight of the body. Ulcers in the hand are mostly 'traumatic' in origin and are caused by burns (cooking, cigarettes), cuts and abrasions. The digital pads, palmar and dorsal aspects of fingers and hypothenar eminence are most often affected. Sometimes, vermin like rats chew up the insensitive fingers or toes of the patient during sleep. To prevent this happening Brand advised patients to keep a dog or a cat as pet to keep the area vermin free. Because they are not painful the wounds are neglected and not allowed to heal by treating them properly, rest. As a result, they continue to remain as festering sores. Often, digital pad infection is allowed to extend deeper and progresses into osteomyelitis of the terminal phalanx, and loss of its distal parts through sequestration. Fingers in leprosy-affected persons get shortened progressively in this manner, sometimes to mere stubs. The infection may also spread proximally, to the flexor synovial sheath and through that involve the spaces of the palm, or, even Parona's space in distal 1/4th of the front of forearm (Fig. 15-10).

Infection of the synovial sheath may also lead to necrosis and loss of flexor tendons of the finger, leaving behind a stiff and straight finger, reducing hand function. Besides the traumatic ulcers, fissural ulcers are also not

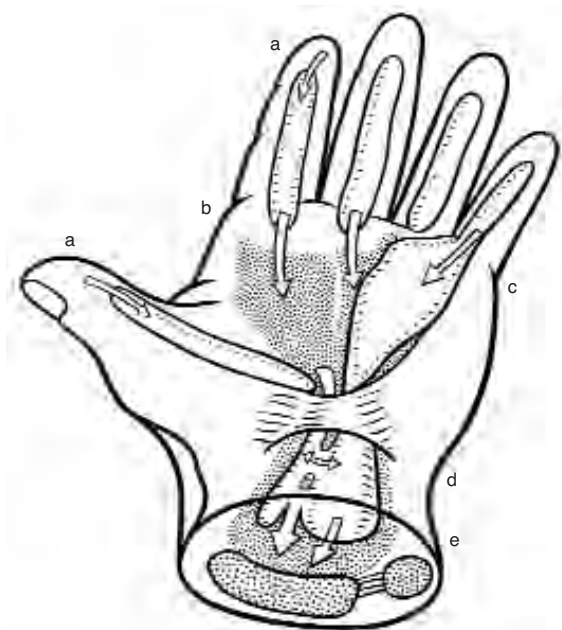


FIGURE 15-10 Spread of infection in the hand: a) from pulp of finger to flexor synovial sheath. b) from flexor sheath to palmar spaces. c) flexor sheath to ulnar bursa. d) from radial bursa to ulnar bursa and vice versa. e) from palmar space (white arrows) and flexor sheath (black arrows) to Parona's space.

uncommon in the hand. Persons doing hard manual labour develop areas of hyperkeratosis in the region of digital creases and the thickened dry skin will crack when the finger is passively straightened during the course of work. In this manner a fissure develops, usually at the site of the middle digital crease or at the proximal digital crease located at the base of the finger. These fissures are initially shallow but in course of time may become quite deep to expose the subcutaneous tissue and even the flexor tendon or its sheath. The fissure is surrounded by grossly hyperkeratotic skin and frequent movement keeps the fissure open and prevents its healing. Secondary infection may enter through the fissure to involve underlying structures with consequences similar to those mentioned earlier.

Pressure and friction sores are also seen in the hand. Friction sores may occur over the dorsum of a finger at the PIP joint level due to rubbing away of the skin and deeper tissues during activities like soaping a garment over a stone. Pressure or friction sores in the hands are seen in persons who habitually use their hands to push the ground down (for getting up), or, downwards and backwards (in order to move forwards). Tips of claw fingers become sclerotic and the sclerotic tissue gets worn out in course of time due to the use of great force used during gripping objects, presenting a small circular sore. Pressure sores in the hand typically occur over the 'heel' (proximal medial (ulnar) corner, i.e., base of hypothenar eminence) of the palm, over the pisiform bone. Infection may spread from an ulcer at this site to the bone underneath and, with continued neglect, spread to the other carpal bones and intercarpal joints, which may result in carpal disorganisation.

MANAGEMENT OF NEUROPATHIC ULCERS

It would be evident from the foregoing discussion that we should aim at achieving three goals: 1. healing of ulcer(s) already present, 2. prevention of recurrence of ulcers that have healed and, 3. prevention of ulceration in individuals with sensory neuropathy, if they are at risk of developing neuropathic plantar or extra-plantar ulcers.

When there is a plantar ulcer, our primary aim is to get the ulcer healed. As the first step, the feet should be carefully examined. Ask the patient whether there is impairment or loss of sensibility in feet and hands, including the affected foot. Although patients' statements in this regard are fairly reliable, it is better to assess sensation.²⁸ People are often not aware of sensory impairment of insidious onset.

Examining the foot with plantar ulcer. Ask for a history of impaired sensibility in the affected foot as well as the other foot and hands, its extent and duration. Use a few explanatory queries such as "Does the ground feel normal while walking? Do you feel the small stones or the hot ground under your feet during walking? Does it hurt when you step on a pebble?" This will confirm that you and the patient have understood each other correctly. Next, even in cases of recurrent ulceration, ask for the details of how the ulcer started originally and what happened subsequently. In the patient's replies, try to identify actual observations from inferences: the patient may say that he had a 'burn' whereas he is not aware of any episode of the burn and had actually noticed only a blister; the patient may say he had an abscess, but only blood stained thin fluid, not pus, drained from the 'abscess'. When asking a leading question such as "Did you have a wound? Did you walk a long distance?" always explain what you mean by the terms used in your question. The terms 'wound' and 'long distance' may not mean the same to the patient as it does to you. The primary aim of examination is to assess the state of the ulcer, whether it is an acute, simple chronic, complicated chronic or a 'recurrent ulcer', in order to determine the line of treatment.

Take time to examine the affected foot with care. In addition, always examine the other foot, and in leprosy affected persons, both hands and both eyes. Look at the affected foot carefully for signs of infection, inflammation, swelling and deformity. Feel the skin for areas of increased temperature ('hot spots'); palpate the bones for thickening and tenderness; move the joints looking for instability and stiffness, and examine the posterior tibial neurovascular bundle, behind the ankle, for tenderness. Pain and tenderness at this site in a patient with a plantar ulcer, but no active leprosy, often indicates chronic inflammation of lymphatics run-

ning along with the posterior tibial vessels and nerve rather than posterior tibial neuritis due to leprosy. Elicit the story of each and every scar. Finally, do not fail to examine the draining regional lymph nodes.

When you notice a deformity in the foot or toes, ascertain whether that was a consequence of previous episodes of ulceration. Find out whether the patient wears any footwear, its type and when she/he uses them. Many patients in rural areas use footwear only on some specific social occasions, like coming to a hospital. Have a good look at the footwear, check its pattern of wear and verify its fit and whether the footwear itself could have caused any damage to the foot.

Carefully examine the ulcer. Note the characteristics like its edges (e.g., scarred / hyperkeratotic / heaped up / rolled out / sloping and healing etc.), the floor (for the presence of slough, nature of the granulation - whether it appears normal, hypertrophic, very pale etc.), openings of sinuses and extent of fibrosis

around the ulcer. Note the nature of the discharge from the ulcer, whether it is copious or scanty, thick or thin, purulent or serous etc. Ask, and look for the presence of fine grains of bone ('bone sand') in the discharge. If sinuses are identified, probe them to identify their track and the presence of any sequestrars in their depths. Finally, note whether the regional lymph nodes are enlarged and tender. The aim and details of management depend upon the type and the condition of the ulcer as identified by clinical examination. Figure 15-11 summarises the aims of management and the principles of treatment of the different types of plantar ulcers.

Management of acute ulcer

The goal of management at this stage is to control the effects of and limit the damage caused by acute infection and inflammation and convert the acute ulcer into a healing ulcer. The acutely inflamed ulcer with oedematous edges and dirty slough-covered floor copiously dis-

Type of Ulcer	Aims and Principles of Treatment
1. Acute Ulcer	Control acute inflammation and convert acute ulcer into a "healing" ulcer and treat it as such, using elevation, cleansing, dressing and, if necessary, antibiotics.
2. Chronic Simple, or, Healing Ulcer	Allow the ulcer to heal, by providing appropriate dressing, and protecting from physical or chemical injury.
3. Chronic Complicated Ulcer	Eliminate complication and convert complicated into a "healing" ulcer and treat it as such.
4. "Recurrent" Ulcer	Identify the cause of recurrence of each ulcer and work out methods to eliminate it. Usually involves scar revision and / or abatement of load on the scar tissue plus special protective footwear.

FIGURE 15-11 Aims and principles of treatment of different types of plantar ulcers.

charging smelling pus is changed to a clean ulcer having thin sloping margins, and its floor covered with healthy granulation, scantily discharging somewhat gummy serous fluid indicating that the ulcer has entered the healing phase. This aim is achieved by: (1) elevating the part, (2) cleansing the ulcer, (3) establishing proper drainage, and, where necessary, (4) using suitable antibiotics. In order to apply the above, the patient with an acutely infected and inflamed (plantar or extra-plantar) ulcer should be admitted as an in-patient in a medical facility, put to bed and prohibited from walking. Minimal necessary investigations would include estimation of hæmoglobin getting a radiograph of the affected part for assessing the possible presence and extent of bone involvement. Other investigations, like estimation of blood sugar, blood culture and culture from the ulcer for identifying the pathogen are done when indicated.

Elevating the part

An essential first step in the management of acute ulcers is elevation of the affected part. Elevation improves venous and lymphatic drainage and reduces œdema. Hanging the limb down adds to tissue tension (and pain) by gravitational effect. Persistent inflammatory œdema leads to fibrosis and contractures of the joints of hand or foot.

Cleansing the ulcer

Cleansing procedures aim at physically eliminating all necrotic tissue and particulate matter, foreign bodies like grit and other detritus as well as floating debris of dead tissue from the ulcer. Soaking the foot daily for about twenty minutes and then irrigating the ulcer with warm normal saline or a mild antiseptic solution will achieve this aim in a few days. Soaking and irrigation are done as often as necessary, twice or thrice a day if need be, depend-

ing on the amount of discharge from the ulcer. Whirlpool baths providing vigorous agitation are very effective in mechanically cleansing acute ulcers. In between sessions of soaking-irrigation, the ulcer is covered with moist dressings, pieces of gauze soaked in a mild antiseptic solution. Deep ulcers, and those communicating with cavities, are loosely packed with a ribbon of gauze soaked in the cleansing agent. "Eusol" (Edinburgh University Solution) containing 1.25 parts each of chlorinated lime (calcium hypochlorite or bleaching powder) and boric acid for 100 parts (w/v) of clean, not necessarily sterile, water is very useful for cleansing purposes, for soaking, irrigation as well as dressing.⁴ Eusol is an effective antiseptic and deodorant and is also much less expensive to make than the other antiseptic agents sold in the market. Eusol has a necrolytic action and the liberated nascent chlorine functions as a mild antiseptic even in the presence of necrotic organic matter.⁶³ Compared with the other buffered hypochlorite solutions like Dakin's and Milton's solutions, Eusol has a lower pH (7.5 to 8.5 cf 9.5 and 10.5 to 11.2) and is therefore less irritating to tissues, although it is not as tissue-friendly as the more modern but much more expensive preparations like hydro-gels and hydro-colloids.^{10,20} Eusol should be freshly made, preferably daily; in any case at intervals of not more than once a week. Non-buffered hypochlorite solutions (e.g., chlorosol) are far more stable than the buffered ones and provide greater available chlorine (about 0.4% cf about 0.25%) but are highly irritating to the tissues as they have very high pH (about 11.5) and so are not used.

Other agents commonly used in moist dressing of plantar ulcers are: concentrated magnesium sulphate, glycerine-magsulphate paste, acriflavine, mercurochrome and hydrogen peroxide. The first two are absorptive dressings as the chemicals used are hypertonic / hygroscopic. They absorb water from the

wound and thus maintain a moist environment congenial for autolytic debridement and wound healing. Hypertonic saline dressings would be equally effective. Acriflavine and Mercurochrome are used mainly for their antiseptic properties, but, except for being colourful and so impressive to the patient and others, they are virtually useless for that purpose as organic matter such as necrotic tissue inactivates them. The nascent oxygen liberated by hydrogen peroxide has an antiseptic effect but one should avoid using hydrogen peroxide for irrigating closed cavities for fear of complications like life-threatening oxygen embolism.^{2,43} Cetrimide BP and chlorhexidine (Savlon™ is a combination of both) are efficient cleansing and antiseptic agents, effective in even low concentrations, and so quite useful as cleansing agents. But, in view of their deleterious effect in vitro on fibroblasts, they are better avoided for repeated use in clean ulcers as they may interfere with fibroblast activity essential for wound contraction and healing.

A variety of other cleansing agents and dressing materials such as polyvinyl film (permeable to O₂ and moisture but not to bacteria), hydro-colloids and hydro-gels, honey, sugar paste, Debrisan™ (a proprietary preparation of micro fine plastic granules that keeps the wound moist by capillary action), collagen sheets and a host of others have been tried in recent times in plantar ulcers of leprosy patients, persons with bed sores, burn wounds and foot ulcers in diabetic subjects.^{15,29,39,64} All of them have been found to be 'effective' in obtaining 'early' wound healing. Even if the claims are valid, it is difficult to say at present how important a place they have in the routine management of ulcers in leprosy, especially in the field. It is also worth noting that a meta-analysis of 47 reports of 35 randomised controlled trials comparing the usefulness of a variety of cleansing agents in chronic wounds concluded "there was insufficient evidence to

promote one ... agent over another".⁵ We must also remember that, in many cases, plantar ulcers in leprosy-affected persons remain unhealed not because some particular dressing agent has not been applied but because they have been neglected and not rested.⁵⁶

Establishing drainage

An important factor in the persistence of infection is damming up of pus in deeper tissues and spaces. Prompt draining away of the infected exudates without allowing them to accumulate is necessary for rapid elimination of infection. Ensuring proper drainage is achieved by surgery. However, extensive surgery involving wide opening up of tissue planes and spaces is contraindicated during the acute stage of the ulcer. Surgery is therefore confined to minimal necessary drainage procedures like incision and release of pent up pockets of pus, making counter incisions in non weight bearing areas for better drainage of deep cavities, removal of loosely lying slough and pieces of dead bone too large to be flushed out by irrigation and loosely packing the wound with gauze ribbon soaked in Eusol. In forefoot ulcers, with acute osteomyelitis of a metatarsal, a 5-cm long dorsal longitudinal counter incision over the maximally affected point to drain the infected site is a useful procedure. The ulcer is dressed from then on through this wound, to promote healing from below. After about two to three weeks of treatment along the above lines, when acute inflammation has subsided, surgical debridement is done (see later) and under antibiotic cover, it may be possible in carefully selected cases to close the plantar wound by sutures (if judged feasible) and continue dressing from the dorsum (Fig. 15-12). The ulcer is thus allowed to heal from the sole upwards. By this procedure one may be able to minimise the scar in the sole. Otherwise, it is treated as a 'chronic/healing ulcer'.




FIGURE 15-12 Diagram of dorsal drainage procedure. **a.** Transverse section showing the extent of joint excision (hatched) and the dorsal corrugated drain. **b.** Elliptical excision of plantar ulcer, sutures in place but not tied (from Fritschi¹³, used with permission).

Use of antibiotics

In the management of acute ulcers, the first general rule is “Do not use antibiotics as a routine”. The second general rule is “Do not fail to use appropriate antibiotics when needed”. The two rules are complementary and not contradictory.

Neuropathic ulceration in general is a chronic condition in the sense that episodes of ulceration and acute inflammation tend to occur repeatedly in many persons. The body defences are adequate to meet the situation and localise the infection in most instances. One can usually obtain control of inflammation, elimination of infection and healing of the ulcer with cleansing, drainage, dressing and debridement procedures alone, without the use of antibiotics. Routine and indiscriminate use of antibiotics randomly, especially in the absence of identification of the offending organism by culture and sensitivity studies, is sure to promote colonisation of the ulcer with antibiotic-resistant bacteria rendering the antibiotics useless when they may be needed urgently. Hence the injunction against routine use of antibiotics.

Notwithstanding the above, appropriate antibiotics must be used when they are indicated. The stress is on ‘appropriate’ and ‘when indicated’. There are ‘absolute’ and ‘relative’ indications for using antibiotics. Absolute indications include life-threatening infective conditions like septicæmia, infection with highly virulent staphylococci and streptococci (necrotising fasciitis), and infection with clostridia. These conditions are medical emergencies in which aggressive antibiotic therapy is indicated for saving the life of the patient. The ‘relative’ indications are the presence of complications indicative of failure of localisation of infection like cellulitis, acute adenopathy of regional lymph nodes and systemic toxæmia. Antibiotics may also be needed in cases of involvement of deeper structures like underlying bones, joints or tendon sheaths. In these cases, the decision to use antibiotics depends on the extent, duration and severity of the local condition.

Plantar ulcers are often contaminated with ‘street organisms’ such as *Staph. aureus* and *E. coli*. That does not mean that they are necessar-

ily the cause of the clinical condition. Culture-sensitivity results from surface swabs of the ulcer are, therefore, not very reliable guides for selecting the suitable antibiotic agent and so have limited value. To get more reliable information, one should culture the needle aspirate from the ulcer bed or from the biopsied tissue from the ulcer. The few reports in the literature on the bacterial flora in plantar ulcers do not always clearly mention whether the source of the culture material was from acute or non-acute ulcers, whether the ulcer was a recurrent one or a first occurrence and whether the swabs had been taken from deep inside the ulcer.^{9,11,14,31,61,66} Therefore, the pattern of bacterial flora in different types of ulcer is generally unknown.

Where the facility is available, one should always attempt to identify the causative pathogen in acute infections by culture of material taken from the depths of the ulcer and its antibiotic sensitivity and administer an appropriate antibiotic or combination of antibiotics. When not available one should use a newer broad-spectrum antibiotic such as the newer penicillin derivatives, quinolones, or a combination of antibiotics, to cover both gram positive and negative organisms.

The acute ulcer will become a 'healing ulcer' in two to three weeks of treatment. All the signs of acute inflammation will have subsided; the discharge will have diminished to scanty, gummy, serous ooze; the floor of the ulcer, now free of all slough, will consist of pink, healthy granulation tissue; and the edges of the ulcer, from being oedematous and inflamed, will have become sloping with bluish epithelium creeping over healthy granulation tissue. Management of a 'healing ulcer' is almost the same as that of 'Chronic (simple) ulcer', except that we need not scrape the ulcer. If any of the above signs are not found, i.e., if inflammation persists, or, purulent discharge continues, or, there is no evidence of healing,

then this suggests the presence of an underlying complication hindering healing. In that case, the ulcer is to be re-evaluated and treated as a "complicated ulcer".

Management of Chronic (Simple) Ulcer

A chronic ulcer, as its name indicates, is one that does not heal easily and even if it heals, it may take a long time to do so (Fig. 15-13). Broadly speaking, there are two reasons for the ulcer not to heal. The ulcer may not heal because of the presence of a complication that interferes with healing, like persistent infection (usually in a deep structure like a bone or a joint), in which case it should be seen as a 'complicated ulcer', or, the ulcer has not been allowed to heal. These, chronic 'simple' ulcers, do not heal because they have been prevented from healing by absence of rest and unprotected walking. Under those conditions, the delicate epithelium growing over the granulation tissue is physically ground down and destroyed by the stresses generated during walking.

'Chronic simple ulcers' are quiescent ulcers

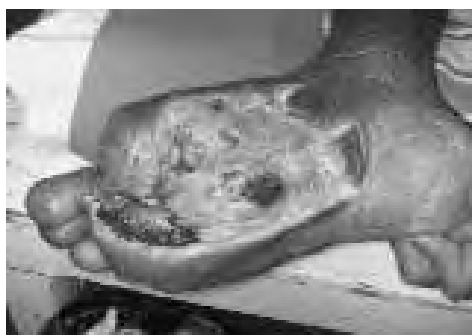

FIGURE 15-13 Late stage of a plantar ulcer.

(i.e., not acutely inflamed), which are also usually superficial. They are usually painless, a few millimetres deep, have punched out appearance, with heaped up hyperkeratotic margins, and have a floor of pale granulation covered with whitish film of fibrin or a thin layer of greyish necrotic tissue. Florid or exu-

berant granulation tissue, protruding from the ulcer ('proud flesh'), indicates the presence of sequestra or foreign bodies deep inside the ulcer. The ulcer bed feels hard because of heavy scarring due to previous episodes of ulceration. There is little discharge from the ulcer, just a spotting of slightly turbid sticky fluid or slight blood staining of the dressing. Pedal pulses are normal. Absent pedal pulses, very pale granulations and practically no bloodstaining would suggest ischemia as the reason for the non-healing of the ulcer. The chronic simple ulcer is best treated by applying a below-the-knee plaster of Paris cast after cleaning the ulcer.³ This method of treatment of plantar ulcers in leprosy patients was first described in the literature in 1939, and its usefulness confirmed a few years later.^{16,19} It became the standard method of treating plantar ulcers, all over the world, only in the '60s after Price published this technique.³⁰ The moulded inner shell of the plaster cast minimises the vertical pressures (compression load per unit area) over the ulcer. By making the sole rigid and by connecting the leg and the foot rigidly, deformation of the foot, during walking, is minimised and the foot gets 'physiological rest'. By avoiding repeated dressing and not allowing any other kind of interference with the ulcer, the process of epithelialisation is protected and healing is promoted.

The ulcer is cleaned with normal saline and dressed with wet saline gauze for a couple of days. It is then gently scraped, with a periosteal elevator or a 10-blade knife, to remove any surface debris and the edges of the ulcer are thinned by tangential shaving off of the thick hyperkeratotic tissue. The ulcer is then covered with a layer of sterile vaseline (petrolatum) gauze, which is packed from above with small pledgets of moist (but not soaking wet) cotton wool so that the Vaseline gauze conforms to the contours of the ulcer and no dead space is left between the gauze and the ulcer. The limb is encased in an adequately, but thinly, padded,

well-moulded, below-the-knee plaster cast (see Appendix D). After 48 to 96 hours, when the plaster cast has dried well (not just hardened but it should have completely dried, as it would break otherwise) it is converted into a walking plaster cast by adding a walking wooden rocker sole. At this stage, it is better to cover the toes completely with a toe cap (after padding the part and allowing sufficient room on the top of the toes for them to bend at their middle joint without rubbing on the toe cap) using plaster bandages. That prevents the front end of the cast shovelling sand and gravel into the cast under the foot. The patient is instructed regarding recognition of a tight plaster cast, how to take care of the limb and the cast, and is then permitted to walk. It is best to measure the feet for appropriate footwear before the plaster is applied and keep them ready for use by the time the cast is removed. Usually, the plaster cast is removed after six weeks, by which time the ulcer should have healed completely. Occasionally a small raw area may still be present that may be treated with a second plaster cast as before or with sticking plaster dressings, without recourse to plaster casting.

Sticking plaster dressing technique

If for any reason the patient refuses to have the plaster cast, especially when the ulcer is small (< 10 to 12 mm) and not deep (i.e., does not extend deep to the deep fascia), or, a plaster cast is not advisable due to poor skin condition, or, we cannot give the cast for some other reason, it is best to resort to the "sticking plaster technique" for treating the ulcer. In this technique, the ulcer is cleaned and the surrounding areas are mopped completely dry (this is very important as the tape will not stick to moist skin), and narrow (3 or 4 mm wide), overlapping strips of ordinary zinc oxide adhesive plaster (coated with ZnO₃ paste) are laid directly over the ulcer without any intervening gauze piece or medication.⁵⁹ The plaster strips

should extend for at least 15 cm, all round, beyond the margins of the ulcer. If the adhesive plaster spans the ulcer, because of its depth, leaving a dead space between the ulcer and the plaster, packing the top of the plaster with small pledgets of cotton wool, or small wads of gauze, and using a bandage or larger pieces of sticking plaster to retain them in position will eliminate the dead space and establish total contact between the ulcer and the plaster strips. The outer bandage may be changed daily or as often as necessary. However, the adhesive plaster dressing is not removed daily but kept on for four to seven days, or, till it starts peeling off. The oily exudate is wiped clean, the ulcer is mopped dry and dressed with adhesive plaster strips, exactly as before. The patient is instructed to keep the plaster dressing as long as possible, avoid walking as much as possible and if the foot gets wet, mop it dry, without removing the sticking plaster strips, at the earliest opportunity. When the foot gets dirty, it is washed well and mopped dry only. Apart from these instructions, there are no other prohibitions. In fact, patients may be given the plaster strips to take home, after teaching them and a member from their family the correct way to apply the sticking plaster strips.²² This technique is very useful, particularly in the field. This useful mode of treating plantar ulcers, was first discussed in connection with venous ulcers by Gilje in 1948 and applied successfully to treat burn wounds and popularised for use in ulcers in leprosy in the late '70s and early '80s by Stenström.^{30,57,60} It was described originally by Paul in Sri Lanka for treating ulcers in leprosy patients in the 1930s!³²

Under treatment, using the sticking plaster technique, the ulcer undergoes autolytic debridement and it heals completely, in the moist environment, in three to eight weeks. The delicate epithelium covering the newly formed scar needs to be protected (with sticking plaster, cotton wool and bandage) for

another three weeks or so before exposing it to direct weight bearing in footwear.

Use of skin grafts

Healing of large (>20 mm) simple ulcers is significantly hastened by covering them with split-thickness skin grafts (medium-thickness, preferably from the instep), after cleaning them up and scraping them. The graft takes in two weeks, but it should be protected for another three to four weeks. Even if the graft does not take, it serves as the perfect dressing for the raw area and the ulcer heals under it. It should be noted that there is great shearing strain at the graft-skin junction because of the difference in the thickness of the two structures and this junction dehisces in course of time. Therefore, it is best to replace the split-thickness graft at the earliest opportunity with a full-thickness skin graft, taken preferably from the dorsum of the foot.

Innumerable methods of treating plantar ulcers are found in medical literature, ranging from local use of a variety of antibiotics, anti-septic agents, vitamins, other chemical, biological and plant extracts, anti leprosy drugs and their derivatives, vasodilators, surgery for improving blood flow in the foot to stretching and surgery on the posterior tibial nerve and perineural injections of vasodilators and other chemicals, magnetotherapy and homeopathy all claiming good results.^{8,38,39} For a critique of such practices readers may consult the papers by Price and Srinivasan.^{36,37,54} Evidently, if any attention is paid to the ulcer, it will usually heal.

We must bring home to the patient that healing is only one stage in the natural history of the ulcer, the next stage being recurrence of the ulcer, that recurrence is not inevitable and that the patient's efforts are needed to achieve that. Therefore, the patient's responsibility to take care of the foot does not diminish or disappear with getting the ulcer healed. In fact it increases and it becomes even more important

that he/she should continue to use protective footwear (indoor as well as outdoor) besides taking other protective foot-care measures. Otherwise, the ulcer is most likely to recur and each bout of recurrence makes it that much more difficult to heal it subsequently.

Management of (Chronic) Complicated Ulcer

One reason for the non-healing of an ulcer is the presence of a complication. The most common complication is the continued presence of a focus of non-specific infection in a deeper structure, which has become infected from the ulcer. Healing is significantly retarded when a sufficient bacterial load (>10⁵ bacteria per gram of tissue) is present. Breakdown of the wound and delayed healing occur when there is 'invasive infection, not just colonization of the ulcer'. The non-specific infection may thus persist in an underlying bone or joint or improperly drained tendon sheath or soft tissue space. This deep site of infection communicates with the exterior through one or more sinus tracks and the wound gets constantly re-infected from the deep pocket. The infection destroys the epithelium, effectively preventing healing of the ulcer. It is evident that we can get the ulcer to heal only if we get rid of the deep focus of infection and this is achieved through surgical debridement. One should attempt to locate the focus of infection by careful clinical examination, systematically examining the whole foot, not just the ulcer site, and all the structures likely to be involved such as bones, joints, tendon sheaths and plantar tissue spaces. Radiographic examination is equally important and that should always be done without fail.

Debridement

In the technical jargon of people working in the field of management of chronic wounds, the term 'necrotic tissue' refers to dead tissue that looks black and is adherent to living tissue,

'non-viable tissue' refers to creamy white stringy non-living tissue that is loosely adherent to live tissue, 'cleansing' is removal of foreign matter from the ulcer and 'debridement' is removal of non-viable tissue from the wound. Based on the means used, ulcer debridement has been described as autolytic, biochemical, mechanical and sharp or surgical.

In *autolytic* debridement we make use of the body's own ability to digest and dissolve non-viable tissue. Occlusive and semi-occlusive dressings, left in place for a few days allow accumulation of the exudates from the wound and permit concentration of white cells, enzymes like elastase and growth factors which help clearance of the necrotic material and promote healing. In adopting plaster of Paris casting and using the sticking plaster technique of dressing chronic ulcers, we are using autolytic debridement to get the ulcer healed.

Biochemical debridement is achieved by using enzymes to digest and dissolve the non-viable tissue. This is particularly useful in sites that are difficult to access for sharp or surgical debridement.

Mechanical debridement is achieved by using the so-called 'wet-to-dry dressing' technique. A moist coarse-meshed gauze is used to cover the wound and it is allowed to dry. Later when the gauze is ripped off, necrotic tissue adherent to the gauze comes off along with the gauze.

In *sharp* or *surgical* debridement the necrotic tissue is removed by sharp dissection using knife and scissors.

Those specialising in treating chronic ulcers, especially burns, decubiti (bed sores) and chronic venous stasis ulcers in the leg have developed the above terminology. Leprosy workers do not make such fine distinctions in terminology while dealing with plantar ulcers. Generally, 'biochemical' and 'mechanical debridement' are not used in leprosy. We use the word 'cleansing' to refer to non-surgical

methods of cleaning up an ulcer. "Debridement" is used more as in the context of acute traumatic wounds to denote surgical cleaning of the ulcer to get rid of all dead and doubtfully viable tissue and hopelessly infected tissue as well as any foreign matter that may be present in the ulcer.

Surgical debridement. A chronic ulcer develops a micro-environment that is hostile to wound healing and different from that of an acute wound.^{66,67} The exudates have a diminished amount of growth factors and the macrophages are less responsive to carry out repair due to senescence, proteolytic activity is increased and there is bacterial contamination in these wounds.^{58,65} All these factors adversely affect wound healing. Furthermore, necrotic tissue is a very good medium for bacterial growth; and the persistent inflammatory activity that results delays the healing process, preventing it from moving on to the next stage of wound repair. It is logical, therefore, to eliminate these hostile environmental factors by surgical debridement and convert the chronic ulcer into an acute wound that has greater potential for healing.¹²

Surgical debridement is the technique of ridding an ulcer of dead and doubtfully viable tissue and foreign material, using surgical dissection in order to achieve healing of the ulcer. This is not a bedside procedure like "scraping the ulcer". During the procedure, every part of the ulcer is systematically attended to as described below.

Ulcer margin. Excise a thin (ca. 1 to 1.5 mm) rim of the edge of the ulcer cleanly using a size 10 or 11 blade knife to get a freely bleeding edge for the ulcer; and thin the thickened and hyperkeratotic margins of the ulcer by tangentially shaving off the superficial layers of the skin, using size 10 blade knife.

Floor of the ulcer. Curette the floor of the ulcer thoroughly using a sharp Volkmann's curette or the sharp edge of a curved periosteal elevator, removing in the process all dead and

devitalised tissue and unhealthy granulation as well as any foreign matter like grit, sand particles, thorns and splinters. Control any bleeding with hot gauze packs. The base of the ulcer is now exposed.

Base of the ulcer: Examine the base of the ulcer visually and by probing carefully for openings of sinus tracks, curette the sinus tracks thoroughly and fully lay them open. Search the deep ends of the sinus tracks for pent up pockets of infection like abscess cavities in bones, joint spaces, tendon sheaths and tissue spaces. These are thoroughly curetted and spiky or rough bone ends are trimmed. Infected tendon sheaths should be curetted in their entirety and proper drainage ensured by appropriate and adequate counter incisions. In the process of dealing with the base of the ulcer, remove all badly infected soft tissue as well as pieces of sequestra and small grains of dead bone ('bone sand') and the rough surfaces of infected ends of bones. In the case of ulcers under the head of the first metatarsal, if found infected and deformed, one should not hesitate to excise the concerned sesamoid bone(s) in toto. At the same time, one should be careful not to remove too much of normal and near normal tissue in the process of debridement. The guiding principle in carrying out surgical debridement is: "*Ruthless excision of all dead and devitalised tissue, but careful conservation of all healthy tissue*". At the end of the procedure, a badly draining deep ulcer with infected sinuses and deep foci of infection will have been converted into a healthily bleeding, freely draining, clean and comparatively shallow wound.

Counter incisions: Wherever felt necessary, one should not hesitate to make adequate counter incisions in order to ensure free drainage. Counter incisions are usually needed over the dorsum of the foot, sometimes along the sides of a toe or the foot, over the proximal part of a tendon sheath, below the ankle or in the region

of the tarsal tunnel for draining infected long flexor tendon sheaths.

Dressings: After completing surgical debridement, the wound is dressed with one layer of Vaseline (petroleum jelly) gauze overlaid with pledgets of moist gauze (in order to eliminate dead space between the wound and the Vaseline gauze), and covered with bulky gauze dressing. The wound is subsequently dressed once a day for a few days and when the discharge from the wound becomes mere blood staining of the gauze, the limb is encased in a

below-the-knee plaster of Paris cast. The cast is retained for at least six weeks. In most cases the wound would have healed by that time. If not, another plaster cast may be applied and retained for another four weeks or longer depending on the state of the residual ulcer. If it is a small, superficial and healing wound we may use the sticking plaster technique described earlier without resorting to a cumbersome plaster cast.

A summary of the management of plantar ulcers is shown in Figure 15-14. While it does not include all contingencies, it shows the

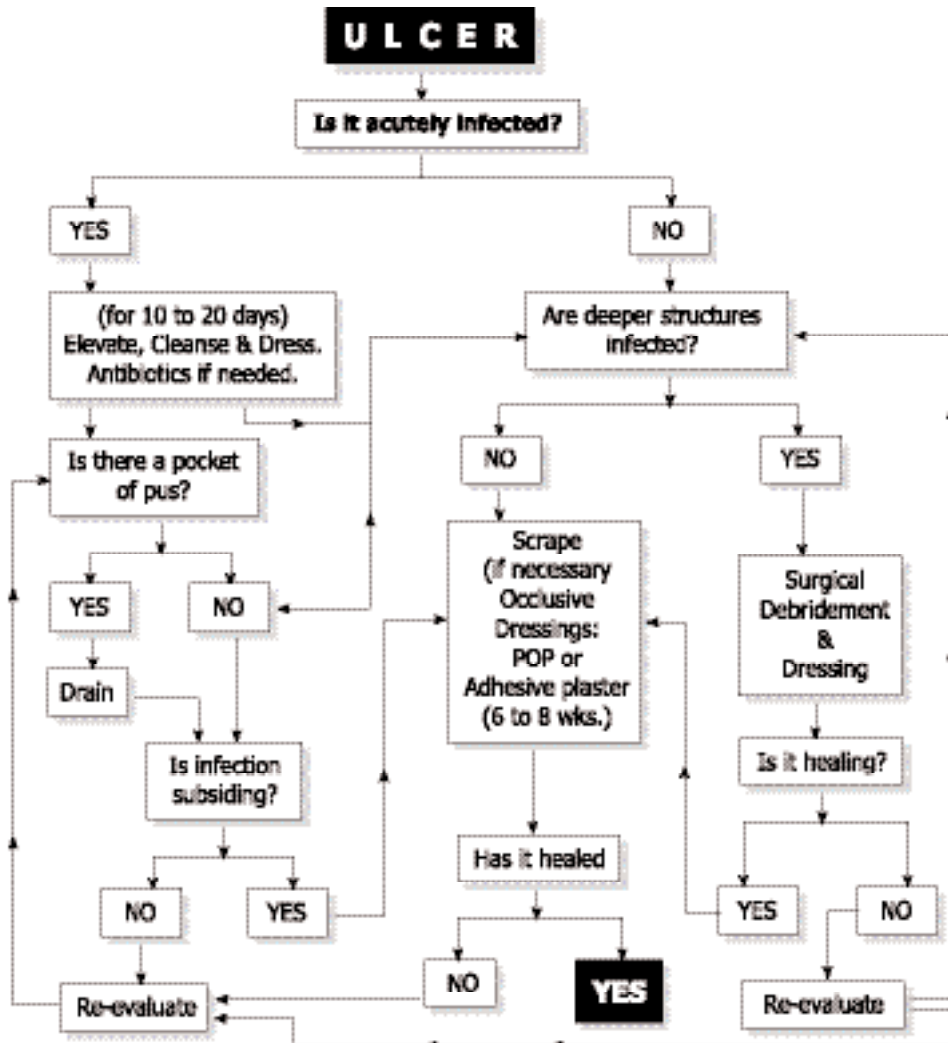


FIGURE 15-14 Decision Tree for the Management of Plantar Ulcer.

major approaches to the management of plantar ulcers. It should also be noted that, in order to avoid complicating the chart further, it does not cover the problem of recurrent plantar ulceration and occasional complications like malignant degeneration.

Other complicating factors

Sometimes, some other feature besides local spread of non-specific infection complicates the situation. The complicating factors include neoplastic degeneration, septicæmia, clostridial infections and deep fungal (and pseudofungal) infection.

Neoplastic degeneration. Chronic ulcers are known to undergo malignant transformation and plantar ulcers are no exception. It is not a very common occurrence and probably not more than 1 to 2 % of plantar ulcers seen in a leprosy hospital will be malignant. Malignant plantar ulcers usually present as 'cauliflower growths' (CFGs), which are proliferative fungating lesions developing in a fairly long-standing ulcer of a few years' duration (see Chapter 18).^{40,42}

Septicæmia. In patients debilitated by inanition, or, in the concomitant presence of debilitating conditions like diabetes or tuberculosis, generalised septicaemia may develop. The condition must be treated promptly and aggressively with parenteral antibiotics and supportive measures, as emergency. Surgery is limited to necessary drainage and debridement procedures only.

Deep fungal infection. Occasionally, the plantar ulcer is complicated by concomitant development of mycetoma ('Madura foot') due to deep (subcutaneous) fungal or pseudofungal infection such as actinomycetes and Nocardia. Considering that chronic plantar ulcers provide excellent opportunities for infection by these organisms, such infections are surprisingly rare and only a few case reports are found in

the literature.^{18,21} In view of its infrequency, there is not enough published information to suggest which one, the mycetoma or the plantar ulcer, is usually the primary lesion and even whether they are related to one another at all. It should also be mentioned that heel ulcers presenting with chronically infected calcaneum and gross thickening of the bone, fibrosis of soft tissue and multiple sinuses around the heel area, clinically indistinguishable from mycetoma, are far more common than mycetomas. In these cases, the diagnosis of mycetoma must be established by diligent search for fungal colonies (white, yellow or black "granules") in the discharges and scrapings from sinuses or by biopsies of deeper tissues.

Prolonged antibiotic therapy and anti fungal medication, for at least six to ten months, combined with repeated debridement of sinuses and abscess cavities in the bones and soft tissues are required for getting rid of these infections.

Clostridial Infection. A chronic wound, especially in the foot, is always in danger of infection with clostridia, especially with *C. tetani*, but the patient rarely develops local or even general tetanus. Occasionally, gas gangrene may supervene. The patient is in a state of toxæmia and collapse and the condition is characterized by severe toxæmia, swelling of the part, crepitus in the subcutaneous tissue and muscles and translucent areas delineating muscles and tissue planes in the radiograph. There is thin bloody discharge from the ulcer and necrotic patches in the limb. While swabs are taken for bacteriological diagnosis, one does not wait for the results to start treatment. Treatment is started on clinical diagnosis. This is a surgical emergency carrying a grave prognosis and calls for emergency amputation, aggressive administration of antibiotics and supportive therapy.

Management of Recurrent Plantar

Ulcers

Recurrence of plantar ulceration is so common a feature that it is “normally” expected to occur. Most people would consider healing as just one stage in the natural history of the ulcer, the next being its recurrence. This is a defeatist view, which could have been valid half a century ago, but not now. It should be emphasised that recurrent ulceration is a preventable condition in almost all instances if the problem is tackled rationally, diligently and with optimism, applying practices of orthopaedics, podiatry and plastic surgery. We should also remember that management of plantar ulceration always has two aims: (a) an immediate aim to get the ulcer healed, and (b) a long-term aim, to ensure that it does not recur.

Recurrent plantar ulcers are of two general types: 1. those that recur because the affected person has not taken normal precautionary preventive measures, and 2. those that recur despite adequate precautionary measures. Most of them belong to the first category and, for their prevention, they require diligent practice of ulcer-preventive practices by the affected persons. However, in a small proportion of patients, the ulcer has already recurred a number of times (because of earlier negligence) and the tissues have suffered such severe damage that ordinary or standard preventive measures are inadequate to prevent recurrence. This type of recurrent ulcers needs additional measures, by way of surgery and/or special footwear, besides standard foot-care practices for their prevention.⁵⁶ These are the ‘true recurrent ulcers’ and their management is discussed in this section.

Causes of recurrent ulceration

Plantar ulcers recur for the following four reasons:

1. *The original causes continue to operate.* The conditions that originally contributed to the development of the ulcer continue to be pres-

ent. They are: denervation and consequent insensibility and dryness of plantar skin, with or without plantar intrinsic muscle paralysis, combined with unprotected and unlimited use of the feet. If normal plantar tissue, structured to withstand walking strains, gave way under these conditions originally, it is not surprising that scar tissue, which is not structured to withstand walking strains, gives way again and again. This is the first kind of recurrent ulcer mentioned earlier. The remedy here is to follow ulcer-preventive foot-care practices, including the use of appropriate protective footwear, diligently.

2. *The scar tissue is of poor quality:* Because of repeated bouts of ulceration and healing the scar at that site becomes dense, brittle, ischaemic and unstable, ready to breakdown even under conditions of less than normal loading. In some feet, the scar is of such poor quality that taking literally half a dozen steps, even with protective footwear, is sufficient to make it breakdown and cause recurrence of the ulcer. The remedy here is to improve the quality of load-bearing tissue, by tissue replacement, or, protect the scar, by some means, preventing the load falling on the scar.

3. *The scar is loaded excessively.* The scar tissue that replaces the normal, finely loculated, subcutaneous fat layer lacks the latter’s springiness and shock-absorbing cushioning effect. Repeated infection or neuropathic bone disintegration may distort the local anatomy by destroying local structures, and these changes result in excessive loading of the scar tissue. This, inevitably, causes early breakdown of the scar and recurrence of ulcer. The remedy here is to protect the scar by modifications in the footwear or by surgically realigning anatomical structures such that the scar is relieved of much if not the entire load.

4. *There is a periodic flare up of infection.*

Lastly, as with infection in the larger bones, infection in the bones of the foot also tends to persist and flare up periodically, with opening up of old sinuses and ulcers and formation of new ones. This kind of acute-on-chronic osteitis happens particularly in feet with infection of the calcaneum or some other major tarsal bone like the cuboid, sometimes in feet with infection of the metatarsal head. Often a minor injury triggers the episode, most probably by producing a local hæmatoma, which would permit an invasive proliferation of the pathogenic organism. The remedy for preventing recurrence of ulcers from this cause is to eradicate the infection with aggressive treatment using all available methods viz., cleansing, repeated surgical debridement and adequate use of effective antibiotics. Occasionally, one may have to resort to radical surgery to get rid of the infected focus. Thus, subtotal resection of the calcaneum (excising much of the body of the calcaneum, leaving behind only the talocalcaneal joints with some bone underneath) has been found very useful to eliminate the hopelessly infected sclerotic bone not amenable to antibiotic therapy.⁵² After this procedure, the patient can walk with any type of footwear in which the heel is built up and cushioned.

We can avoid recurrent ulcers by a) having the patient diligently practising foot-care procedures including constant use of appropriate protective footwear and b) eradication of infection locally. If the ulcers still recur, the foot is evaluated afresh and, depending on the local condition, c) replacement of the scar with better quality tissue and, d) use of surgical and non-surgical measures to relieve the load on the scar will help prevent recurrence of these ulcers.

Foot-care (see also Appendix C)

The denervated feet of affected persons are substandard structures, both structurally and functionally, and they require special care measures to maintain their integrity without

which they will invariably breakdown. The dry, anhidrotic and insensitive plantar skin (sole) should be cared for properly to avoid development of cracks and fissures, which are precursors to ulcers. Further, in many leprosy-affected persons, the foot is structurally weakened because of muscle paralysis and walking with such weakened feet without protective footwear damages the plantar tissues, especially the subcutaneous fatty layer that acts as shock-absorbing cushion, and causes ulceration. Therefore, we need 1. 'skin care' practices to keep the skin intact and avoid it breaking up, and 2. 'walking-care' practices to permit walking without exposing the foot to the danger of ulceration.

1. 'Skin care' practices have two different aims: a) keeping the skin soft and supple. Otherwise the denervated, dry skin develops cracks which become portals of entry of infection leading to ulceration; and, b) protecting the insensitive skin from being wounded from without. The first aim of keeping the sole soft and supple is achieved by the procedure of daily soaking, scrubbing and smearing with oil. The foot is soaked in soapy water or saline for ten minutes, the sole is scrubbed with a pumice stone or any similar object with a rough surface to scrape off superficial keratin layers, washed, mopped to remove the excess moisture and smeared with some oil, preferably one which will not attract ants and other vermin (e.g., neem (margosa) oil or castor oil). This procedure should become a daily habit, like brushing one's teeth. If the patient can afford it, moisturising lotions could be used, though this is less effective than soaking and oiling. The second aim of preventing wounding of the sole (by nails, thorns, sharp stones or hot surfaces) is achieved by using footwear with tough soles. Such footwear should be worn, preferably all the time one is on one's feet or, at least every time the person goes out of the house, and not just on some special occa-

sions (like going to the weekly village fair or going to the town for seeing a cinema), as is the habit with some people. While leprosy institutions provide their clients footwear with tyre soles for this purpose (because of considerations of cost), those who can afford it can use commercially available modern, lightweight, durable and tough soles made of synthetic material. While plantar skin is protected by footwear, using gloves when handling hot or rough objects protects palmar skin. This topic is dealt with in detail elsewhere.⁵⁵

2. *Reduction of walking strains.* The second aim of protecting the feet from walking strains is achieved by two strategies namely: a) reducing the duration of walking, avoiding walking long distances and using a vehicle if one has to do so; and b) using appropriate protective footwear (with suitable modifications and inserts depending on the local condition of the foot) in order to reduce the strains on the feet during walking.

When the foot is merely anaesthetic, as mentioned earlier, the foot only needs to be protected from being injured from without and this is achieved by having a tough outer sole to the footwear. Where there is plantar intrinsic muscle paralysis in addition, a shock-absorbing, pressure-reducing modification is needed and this is achieved by the addition of a soft springy insole to the footwear. Microcellular rubber (MCR) that will mimic the action of the normal subcutaneous layer in the sole of the foot is the material most often used for this purpose. The average hardness of the normal (unscarred) human sole is about 20 shore 'A' (personal observation in South Indian patients who were not using footwear as a routine). MCR of similar, or preferably slightly less (say, 15 shore A), hardness is to be used in the routine footwear intended for leprosy affected persons having plantar intrinsic muscle paralysis besides loss of sensibility in the sole. If the foot has already had ulcers, the scar may be protect-

ed by additional modifications such as a rigid sole-rocker, metatarsal bar, extended heel or arch support (Chapter 17).

Improving quality of scarred site

Durability of the scarred weight-bearing site is obtained by replacing the unstable scar with tissue of better quality, or by shifting the scar to a non-weight-bearing locale. Figure 15-15 lists the common methods of achieving this aim.

Where feasible the scar is excised, the

Scar excision and wound closure by:

- Suture or skin graft
- Local flap or distant flap
- Island pedicle flap or free flap, or,
- Shifting scar to non-weight-bearing site

FIGURE 15-15 Means of improving scar sites.

wound edges are undermined and the wound is closed by direct suturing. If possible, a subcutaneous fat flap may be interposed between the scar and the deeper tissues in order to improve the shock-absorbing quality of the weight-bearing site.⁴⁶

When closure by excision and re-suture is not feasible, skin grafting may be done to cover the raw area. Depending on the local condition, we may use split-thickness or full-thickness skin graft. Split-thickness graft may be taken from the sole itself, from a non weight-bearing area like the instep. The dorsum of the foot is a good donor site for full-thickness skin graft in the sole of the foot.

Use of local flaps. Using a local flap, mobilised from around the ulcer may be a better way to cover the raw area resulting from excision of the scar. This has the advantage of providing tissue very similar to the one that was lost due to ulceration. Small to medium sized unstable adherent scars in the middle of the heel are so excised as to give an antero-posteriorly oriented oval or lens-shaped wound.

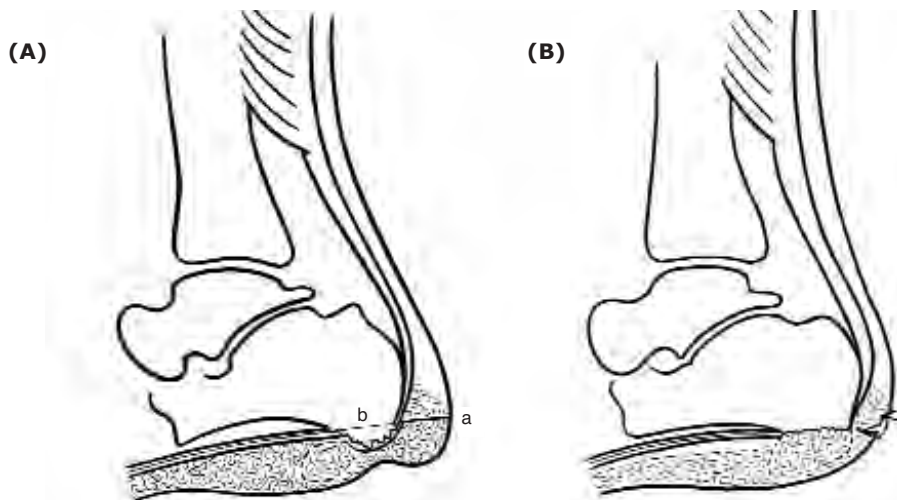


FIGURE 15-16 Improving scar site. Schematic illustration of the procedure: Interposition of subcutaneous fat flap between bone and skin combined with bumpectomy to reduce load on scar in heel. **A.** a) incision for exposure. b) level of bump excision. c) incision for mobilising subcutaneous fat flap. **B.** Following completion of the procedure.

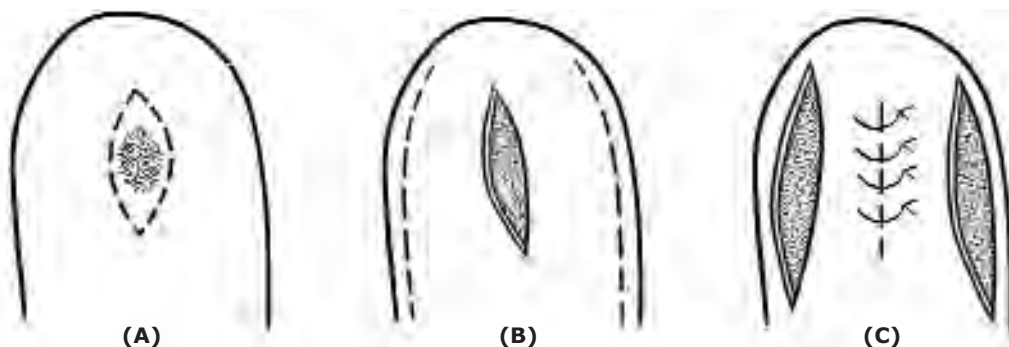


Figure 15-17 Scar excision and skin closure in heel using a bi-pedicle (buckle handle) flap **A.** Scar in heel and incision for excising the scar **B.** Scar excised; incisions in the margins of the heel for mobilising bi-pedicle flaps. These incisions should be longer than the gap in the skin and should be made in the non weightbearing area **C.** Bucket handle flaps mobilised and central gap closed without tension to provide a linear (and stable) scar in place of the broad, adherent (and unstable) scar.

This wound is then closed by raising two bucket-handle flaps from the two sides of the central wound, by making two release incisions, one on each side of the lateral margin of the heel, and suturing them together to provide a linear scar in place of the earlier unstable broad scar (Fig. 15-17).

The release incisions made for raising the bucket handle flaps should be longer than the central wound in order to ensure tension-free

closure.⁵⁰ An adherent and unstable scar under a metatarsal head may be excised and closed in his manner except that here the wound created by excising the ulcer is transversely oriented and the release incision (which should be longer than the wound to be closed) is also made transversely, about 20 mm to 25 mm anterior to the creases at the bases of the toes.

Another way of raising a local flap of good

quality to replace a scar is to fillet a toe (i.e., remove all the remnants of phalanges in the toe leaving behind only the soft tissue) and use the now available skin of the toe for closing the raw area created by excising the unstable scar (Chapter 16). This procedure is indicated when the unstable scar is located under the head of a metatarsal, whose toe (or its neighbour) has become a functionless flail appendage and a positive nuisance while wearing footwear because of previous ulceration. Instead of amputating and discarding such a toe, it may be filleted and the soft tissue used for scar replacement as mentioned above.

We may also use a rotation flap to cover the raw area resulting from excision of an unstable scar. The scar is excised using a triangular incision and one side of the triangle is extended as a widely sweeping curve. A back cut of adequate length is made, sufficient to mobilise the flap to fully cover the wound created by scar excision but not so long as to endanger the blood supply of the flap. The flap is rotated to cover the raw area and sutured, using, if necessary, a free skin graft to cover any raw area in the region of the back cut.

The local flaps mentioned thus far are within the capabilities of a competent surgeon interested in this kind of surgery. There are other flaps, local and distant, like artery pedicled island flaps and composite (free) flaps, which have been found useful in dealing with recurrent ulceration, but they require specialist (plastic / microvascular) surgical expertise (Chapter 16).²³⁻²⁷

Shifting scar to non weight-bearing site. When the ball of the foot is badly scarred and normal protective precautions by way of foot-care and walking-care, including modifications in the footwear, are unable to prevent the breakdown of the scar, one may resort to diverting the body weight away from the scar (e.g., patellar

tendon bearing (PTB) orthosis), or, diverting the scar out of the way of body weight. We may achieve the second aim by doing a transmetatarsal amputation (bone section just distal to the bases of the metatarsal bones) and closing the wound using a long plantar flap incorporating the unstable scar near its distal end. When the flap is turned over to cover the wound, the scar is automatically shifted to the dorsum or the front end of the foot, escaping weight-bearing, and weight is now borne by normally structured plantar tissue (Fig. 15-18).

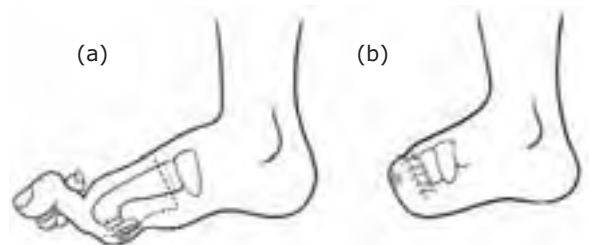


FIGURE 15-18 Transmetatarsal amputation for preventing recurrent forefoot ulceration.
a. Grossly deformed toes and unstable and adherent forefoot scar. Interrupted line shows skin incision to give a long plantar flap. Dotted line shows the level of bone section, preserving the proximal one-inch of the metatarsal.
b. Amputation completed. Note suture line is on the dorsal side and the scar has been shifted to a non-weightbearing site of the foot.

Reducing stress on the scar

Another reason for frequent recurrence of the plantar ulcer is that the scar, which is already of poor quality, is further subjected to excessive stress during walking. The site of excessive stress and its relation to the scar may be demonstrated by taking footprints, preferably using a Harris mat, but they can be taken even without it. The scar may be relieved of excessive stress by introducing modifications in the footwear or by surgery (Chapter 16, 17).

CONCLUSION

It should be made clear that there are no set solutions, like cookery recipes, telling us what to do for a given ulcer, because each foot, and each ulcer in a given foot, has a unique history and morbid anatomy of its own. Nevertheless, with the knowledge of the varieties and patterns of stress and loading that a foot is subject to during standing and walking, one can work out a solution for relieving the particular stress in the given case. This means that one should examine the foot very carefully, and study each ulcer in that foot, develop a plausible hypothesis about how the ulcer is stressed during standing and walking and, work out a method of eliminating that stress based on that hypothesis.^{48,51} The following case summaries illustrate this approach.

CASE 1. PRN (male, 37 years). Problem: Frequently breaking down ulcer in the region of proximal phalanx (area between the two digital creases on the plantar surface) of right big toe. Ulcer starts as a crack in the old scar, and the crack widens into an ulcer. No involvement of bone or tendon sheath or chronic local infection. Plantar anaesthesia present. No plantar intrinsic paralysis. Hypothesis: The relatively unyielding scar gets unduly stretched during walking causing it to breakdown. Proposed solutions: 1. Replace scar with tissue that can stretch better or, 2) eliminate the stretching stress by making the plantar tissues of the big toe lax, by shortening the skeleton of the toe.

The second solution was adopted and excising the distal half of the proximal phalanx shortened the toe. Follow-up 18 months later showed no recurrence of the ulcer.

CASE 2. RK (male, 28 years). Problem: Frequently recurring ulcer in left foot under 3rd metatarsal head (MTH). Originally started as an area of hyperkeratosis under MTH 3, which broke down and developed into an

ulcer. No underlying deep infection. Footprint shows very high pressure under MTH 3. Plantar anaesthesia present, no plantar intrinsic paralysis. Hypothesis: Head of 3rd MT wedge shaped giving rise to high pressure under this MTH. Proposed solution: Duvries' condylectomy (through a dorsal approach, tangential excision of the undersurface of the MTH making it flat (instead of being wedge shaped) and thus enlarging the weight-bearing area many times).

This was done. Follow-up 11 months later showed no recurrence. Footprint showed no high-pressure sites.

CASE 3. RM (male, 35 years). Problem: Recurrent ulceration of terminal pad of 2nd toe (left foot). Earlier had ulcer of big toe pad and during one episode of severe infection the big toe was removed. Second toe ulceration started some months later. Ulcer over pulp (terminal pad) of 2nd toe with no bony involvement and no big toe. Second toe much longer than the others. Anaesthesia medial half of sole with paralysis of muscles supplied by medial plantar nerve. Walking footprint shows dragging of tip of 2nd toe with high pressure. Hypothesis: In the absence of big toe, tip of the 2nd toe bears most of the stress of transfer of load from the foot. Proposed solution: Shorten the 2nd toe so that it is level with the others so that all four toes share walking stresses and reduce that on the 2nd toe.

This was done by excising the middle phalanx of the 2nd toe. Follow-up one year later showed an ulcer-free 2nd toe.

CASE 4. MS (male, 19 years). Problem: Frequently recurring ulcer under first MTH (right foot). Started with ulcer under MTH3 many years ago followed later by ulceration under MTH 1. Foot shows a deep cleft under MTH3, dorsal migration of 2nd and 3rd toes, and severe secondary hallux valgus with thin adherent scar under MTH1. The 1st MTH ulcer heals without difficulty, but recurs promptly on

walking (with protective footwear) even for a day or so. Footprint shows high-pressure area under MTH1. Hypothesis: Repeated ulceration led to loss of head and distal shafts of 2nd and 3rd metatarsals with shortening of these rays and dorsal migration of the central toes followed by hallux valgus because of loss of lateral support to big toe. Hallux valgus rendered the big toe useless permitting severe overloading under MTH1. Proposed solution: Correct hallux valgus, release the dorsal scar and bring the toes forward and retain them in that position by fusing the 2nd toe with the big toe and 3rd toe with the 4th (surgical syndactylia).

This was done. Seen eight months later, the foot was ulcer-free.

CASE 5. VKR (male, 28 years). Problem: Recurrent ulceration under 3rd and 4th MTH for the last seven years. Ulcer recurs despite protective footwear and foot-care practices. End-on (frontal) view of non weight-bearing foot shows severe 'reversal of the distal transverse metatarsal arch' (the metatarsal heads describe an arch with convexity towards the ground). Third degree clawing of 2nd, 3rd and 4th toes (flexion contracture of PIP joint, dorsal migration of toe with the base of proximal phalanx of the toe resting on the neck of its metatarsal and the MTH can be felt in the sole, like a pebble just under the skin). Walking footprint shows high pressure area under 2nd, 3rd and 4th MTH's. Hypothesis: Because of the 3rd degree claw deformity, the concerned MTH is pushed down by the PP of the toe during walking (during contraction of FDL and EDL muscles). Proposed solution: Reduce the dislocation of MTP joints, re-position the toes to lie in front of their MTH's instead of lying on top of them, straighten the toes and lift up the "fallen" metatarsal heads by transplanting concerned EDL tendons to the necks of their respective metatarsals (proximalization of EDL).

This was done through a dorsal approach. Follow-up for five years showed no recurrence of the ulcer.

CASE 6. M (female, 31 years). Problem: Recurrent ulcer in middle of left heel. Adherent scar in the middle of the heel with a bony mass just under the scar. X-ray with marker over the scar shows abnormally prominent calcaneal tubercle directly above the scar. Hypothesis: Scar breaks down due to excessive shearing and compression during walking. Proposed solution: Convert broad adherent scar into thin linear scar-by-scar excision and resuture and enlarge bony weight-bearing surface by excising the bossy calcaneal tubercles to provide a larger, flat surface. If feasible, interpose between bone and scar, a local fat flap mobilized from one side.

This, including fat flap interposition, was done. Seen 14 months later, the ulcer had not recurred.

CASE 7. JM (male, 57 years). Problem: Recurrent ulceration of both heels for many years, despite use of protective footwear and practicing foot-care. Has sound scar in mid heel. Ulcer found in anterior heel area. X-ray (with marker over ulcer) shows secondary calcaneus recurvatus deformity ("boat-shaped calcaneum") with ulcer under the front end of calcaneum. Subtalar articulation is intact. It is this ulcer that keeps recurring now. Hypothesis: The posterior pillar of longitudinal plantar arch has been lost because of the bony deformity. Therefore, during heel strike, the front end of calcaneum hits the ground and this is the reason for recurrent ulceration under front end of heel. Proposed solution: Restore posterior pillar to produce normal heel strike. This was done by doing a displacement osteotomy of calcaneum. Seen 18 years later, the heel was ulcer-free.

It should be evident from the above illustrative case summaries that a plantar scar may be

overloaded due to dynamic and/or static stresses, because of obvious, or not so obvious or even occult, anatomical abnormalities (e.g., talipes, congenital varus 5th toe and wedge shaped MTH respectively). Our experience shows that it is worth taking the trouble and spending time to identify the exact cause of recurrence and eliminate it. The expertise required is eclectic and techniques from the disciplines of orthopaedics and plastic surgery are needed for surgery in this field.

REFERENCES

1. Basmajian JV: *Muscles Alive: Their Functions Revealed by Electromyography*. Baltimore, Williams & Wilkins, 1962
2. Bassan MM: Near fatal systemic oxygen embolism due to wound irrigation with hydrogen peroxide, *Postgrad Med* 58:448-451, 1982
3. Birke JA, Novick A, Hoard A, et al.: Methods of healing plantar ulcers in Hansen's disease patients. *The Star* 51:5-10, 1992
4. Bloomfield SF, Sizer TJ: Eusol B.P.C. and other hypochlorite formulations used in hospitals. *Pharm J* 235:153-157, 1985
5. Bradley M, Cullum N, Sheldon T: The debridement of chronic wounds: a systematic review. *Health Techn Assess* 3, No. 17, 1999
6. Brand PW: Pressure sores: the problem. pp.19-23. In Kenedi RM, Cowden JM, Scales JT(eds): *Bed Sore Biomechanics*. Macmillan, London, 1976
7. Brand PW: *Insensitive Feet: a practical handbook on foot problems in leprosy*, 3rd ed. The Leprosy Mission, London, 1991
8. Chakraborti D, Datta S, Chakraborti T: Trial of homeopathic medicine in the prevention of disability. *Proceedings 16th International Leprosy Congress, Salvador, Brazil*, pp. 314, 2002
9. Cherian E, Vanaja G, Krishnan R, Bhatia VN: Bacterial flora of ulcers treated by three types of dressings. *Ind J Lepr* 60:389-391, 1988
10. Dakin H.D: On the use of certain antiseptic substances in the treatment of infected wounds. *Brit Med J* 11: 318-320, 1915
11. Ebenezer G, Daniel S, Suneetha S, et al: Bacteriological study of pus isolates from neuropathic plantar ulcer associated with acute inflammatory phase. *Ind J Lepr*, 72:443-449, 2000
12. Ehrlich HP: Why wounds need to be debrided. pp. 23-29. In Westerhof W and Vanscheidt W (eds): *Proteolytic Enzymes and Wound Healing*. Springer, Berlin, 1994
13. Fritschi EP: *Surgical Reconstruction and Physical Rehabilitation in Leprosy*. The Leprosy Mission, Delhi, 1984
14. George M, Bhatia VN, Kar HK, Roy RG: Anaerobic flora in trophic ulcers in leprosy patients. *Ind J Lepr* 57: 336, 1984
15. Gorse GJ, Messner RL: Improved pressure sore healing with hydrocolloid dressings. *Arch Dermat* 123: 766-771, 1987
16. Haythornthwaite HW: Closed plaster for trophic ulcers. *Lepr India*, 15:20-22, 1943
17. Impey SP: *Handbook of Leprosy*. J&A Churchill, London, 1896
18. Jayakumar J, Aschoff M, Renuka G: Mycetomas in leprosy. *Ind J Lepr*, 65:229-233, 1993
19. Khan JS: Treatment of leprosy trophic ulcers. *Lepr India* 11:19-21, 1939
20. Kozol R.A., et al: Effects of sodium hypochlorite (Dakin's Solution) on cells of the wound module, *Arch Surg* 123: 420-423, 1988
21. Kulkarni RB, Patil RT, Praveena S: Actinomycotic mycetoma due to *Nocardia brasiliensis* in a case of leprosy. *Ind J Lepr* 73:263-265, 2001
22. Kumar A, Laxmanan M: Adhesive zinc tape treatment of uncomplicated ulcers amongst leprosy patients. *Lepr Rev* 57:45-91, 1986
23. Liwen D, Futian L, Zaimeng W, Juan J: Techniques for covering soft tissue defects resulting from plantar ulcers in leprosy: General considerations and summary. *Ind J Lepr* 71:279-295, 1999
24. Liwen D, Futian L, Juan J, Guocheng Z: Techniques for covering soft tissue defects resulting from plantar ulcers in leprosy-2: first toe web and dorsal foot flaps. *Ind J Lepr* 71:297-309, 1999
25. Liwen D, Futian L, Jugen Z, Yongling Y, Juan J, Guocheng Z: Techniques for covering soft tissue defects resulting from plantar ulcers in leprosy-3: use of plantar skin or musculocutaneous flaps and anterior leg flap. *Ind J Lepr* 71:3-16, 1999
26. Liwen D, Futian L, Juan J, Guocheng Z: Techniques for covering soft tissue defects resulting from plantar ulcers in leprosy-4: use of medial leg flap and medial knee flap. *Ind J Lepr* 71:17-30, 1999

27. Liwen D, Futian L, Juan J, Guocheng Z. Techniques for covering soft tissue defects resulting from plantar ulcers in leprosy-5: use of the flap in the inguinal region and latissimus dorsi musculocutaneous flap. *Ind J Lepr* 72:227-244, 2000
28. Malaviya GN, Husain S, Girdhar A, Girdhar BK: Sensory functions in limbs of normal persons and leprosy patients with peripheral Trunk damage. *Ind J Lepr* 66:157-164, 1994
29. Molan PC: Honey as a dressing for wounds, burns and ulcers: a brief review of clinical reports and experimental studies, *Primary Intention* 6: 148-158, 1998
30. Ovington L: Wound dressings: their evolution and use. pp221-232. In V.Falanga, (ed): *Cutaneous Wound Healing*. Martin Dunitz, London, 2001
31. Palande DD, Desevery C, Rajagopalan MS: Plantar ulcers with osteomyelitis underneath. A bacteriological study. *Lepr India* 49:322-329, 1977
32. Paul M: Surgical measures in leprosy. *Int J Lepr* 4: 29-34, 1936
33. Price EW: Studies on plantar ulceration in leprosy. *Lepr Rev*, 30:98-105, 1959
34. Price EW: The natural history of plantar ulcers. *Lepr Rev*, 30:180-183, 1959
35. Price EW: The etiology of plantar ulcers. *Lepr Rev* 30:242-248, 1959
36. Price EW: The complications in plantar ulcers. *Lepr Rev* 31:97-103, 1960
37. Price EW: Plantar ulcers in leprosy: A review of the literature. *Lepr Rev* 32:108-116, 1961
38. Raghupathi SG, Subramanyam S, Deenabandhu A et al.: Exposure to pulsed magnetic fields in the treatment of plantar ulcers in leprosy patients: a pilot, randomised, double blind controlled clinical trial. *Ind J Lepr* 69:241-250, 1997
39. Rao KS, Mahendra Kumar, Oommen PK et al.: Collagen sheet and its usefulness in healing ulcers in leprosy patients. *Ind J Lepr* 59:435-441, 1987
40. Richardus JH, Smith TC: Squamous cell carcinoma in chronic ulcers in leprosy. A review of 38 consecutive cases. *Lepr Rev* 62:381-387, 1991
41. Ross FW: Aetiology and treatment of plantar ulcers. *Lepr Rev* 33:25-40, 1962
42. Sane SB, Mehta JM: Malignant transformation of trophic ulcers in leprosy: a study of 12 cases. *Ind J Lepr* 60: 93-99, 1988
43. Sleigh JW, Linter SPK: Hazards of hydrogen peroxide. *Brit Med J* 291:1706, 1985
44. Srinivasan H: Trophic ulcers in leprosy-I: distribution of ulcers in the sole of the foot. *Lepr India* 35:119-127, 1963
45. Srinivasan H: Trophic ulcers in leprosy-II: ulceration and plantar intrinsic paralysis. *Lepr India* 36:110-118, 1964
46. Srinivasan H, Mukherjee SM: Trophic ulcers in leprosy III. Surgical management of chronic foot ulceration. *Lepr India* 36:186-193, 1964
47. Srinivasan H: Plantar ulcers and corrective surgery: determining factors in localization of foot ulcers in leprosy patients. *Lepr India* 37 (Suppl 3A): 3-8, 1965
48. Srinivasan H: Reconstructive surgery and prevention of neuropathic plantar ulcers. In *Proceedings of International leprosy Seminar, Agra, 1967*. Published by Ministry of Health, Government of India, New Delhi, 1967
49. Srinivasan H, Desikan KV: Cauliflower growths in plantar ulcers in leprosy. *Lepr India* 43:24-32, 1971
50. Srinivasan H: Heel ulcers in leprosy patients. *Lepr India* 48:355-361, 1976
51. Srinivasan H: Reconstructive surgery for correction of deformities of foot and for prevention of recurrent plantar ulceration. pp 637-649. In Dharmendra (ed): *Leprosy-Vol. 1*. Kothari Medical Publishing House, Bombay, 1978
52. Srinivasan H: Surgery of os calcis in leprosy patients. *Bull Tamil Nadu Orthop Assn*, 28-32, 1981
53. Srinivasan H: Prevention of recurrent neuropathic ulceration of the forepart of the foot. *Ind J Surg* 44:300-304, 1982
54. Srinivasan H: Do we need trials of agents alleged to improve healing of plantar ulcers? *Lepr Rev* 60:278-282, 1989
55. Srinivasan H: Prevention of Disabilities in Patients with Leprosy. Geneva, World Health Organization, 1993
56. Srinivasan H, Palande DD: Essential Surgery in Leprosy: techniques for district hospitals. pp.18-35. Geneva, World Health Organization, 1997
57. Süderberg T et al: Treatment of leprosy wounds with adhesive zinc tape. *Lepr Rev* 53:271-276, 1982
58. Stadelman WK, Digenis AG, Tobin GR: Impediments to wound healing. *Am J Surg* 176 (Suppl. 2A):39S-47, 1994

59. Stenstrøm S, Bergman G, Bergman S: Wound healing with ordinary adhesive tape. *Scand J Plast Reconstr Surg* 6: 40, 1972
60. Stenstrøm S et al: Leprosy wound healing with ordinary adhesive tape: a preliminary report. *Scand J Plast Reconstr Surg* 10:241, 1976
61. Sturm AW, Jamil BMC, Adam KPWJ et al: Microbial colonizers leprosy skin ulcers and intensity of inflammation. *Int J Lepr* 64:274-281, 1996
62. Tarnuzzer RW, Schulz GS: Biochemical analysis of chronic and acute wound environments. *Wound Rep Reg* 4:321-325, 1996
63. Taylor HD: The solvent action of antiseptics on necrotic tissue. *J Exp Med* 27:155-164, 1918
64. Tudhope M: Management of pressure ulcers with a hydro-colloid occlusive dressing: results in twenty-three patients, *J Enterostomal Ther* 11:102-105, 1984
65. Vande Berg JS, Rudolph R, Holan C, Haywood-Reid PL: Growth factors and chronic wounds: Fibroblast senescence in pressure ulcers. *Wound Rep Reg* 6:38-49, 1998
66. Vinodkummar CHD, Harikrishnan S, Bhatia VN, Rot RG: Bacteriological study of trophic ulcers in leprosy patients. *Lepr Rev* 55: 504, 1983
67. Yager DR, Chen SM, Ward SI et al: Ability of chronic wound fluids to degrade peptide growth factors associated with increased levels of elastase activity and diminished levels of proteinase inhibitors. *Wound Rep Reg* 5:23-32, 1997

Role of Flaps and Skin Grafts in the Management of Neuropathic Plantar Ulcers

• P.E. GRAVEM

INTRODUCTION

When I for the first time saw leprosy patients at ALERT Hospital, Addis Ababa in 1986, I was taken by surprise seeing so many people walking around on seriously neurologically impaired feet. Most of them were relatively young people who had to walk a lot in order to earn their daily living. Foot ulcers were very common. As a plastic surgeon, I was familiar with covering tissue defects of different kinds with skin grafts and flaps. I must say I started off rather enthusiastically trying to cover many plantar ulcers, believing that time could be saved and that the quality of life could be improved for many patients by an active surgical approach to the ulcer problem. When I look back today, the only group of patients I feel really benefited from modern plastic surgical procedures, and actually got a “new foot”, was a rather small but still important group of patients with big heel defects, ulcers as well as unstable scars. The medial plantar island flap turned out to be very successful and represented a real improvement compared with surgical procedures described in more traditional textbooks for surgeons dealing with leprosy related problems. Otherwise, it is also my experience that one often can be quite conservative waiting for secondary healing of the majority of plantar ulcers in leprosy. Of course, the basic principles of pressure point reduction and adjustment of footwear must be addressed. But there are exceptions, and covering procedures sometimes have to be considered.

GENERAL CONSIDERATIONS

The skin and underlying soft tissue of the sole of the foot is anatomically unique and damage to the weight bearing portions requires reconstruction by similar tissue for the best long-term results. There seems to be an innate mechanical property of the sole itself that gives it capacity to bear weight and to withstand shear, which is very important in preventing ulceration, as is sensation.^{6,7} The firm adhesion of skin to plantar fascia limits skin mobility and makes it a firm-gripping pad for heavy traction. Therefore, local flaps are employed whenever possible. As a main principle, tissue from a non-weight bearing area of the foot is moved into a weight bearing area and the donor site may or may not have to be covered with a skin graft.

Before considering any surgical procedure to introduce new tissue in an ulcerated plantar area, the cause of the ulceration must be analyzed. Methods of preventing recurrent ulceration can be deduced from a study of the mechanism resulting in ulceration. Often it is obvious, such as infected wounds and cracks. In these cases general foot- and skin care is of uttermost importance in preventing re-ulceration. Another large group of ulcers has a tendency to persist without treatment and rest, and to relapse on the resumption of walking with a considerable risk of deep infection and consequent deformity and destruction of the foot. Such ulcers are usually pressure sores over a bony prominence. In such a case, to perform skin grafting or to do a beautiful flap

without being able to reduce the pressure of which the ulcer was caused, is useless and a waste of time. Only footwear modification or bone surgery, or both can reduce the harmful pressure in such areas. The surgery may consist of simple osteotomy of a bone spur or an arthrodesis to realign the foot.

METHODS OF COVERAGE OF ULCERS

Distant Skin Flaps

Multiple distant flaps (i.e. cross thigh flaps, cross groin flaps, buttock skin flaps, free muscle flaps covered with split skin graft) with tissue not specialized to withstand walking, are described in the literature to cover plantar defects. Patients with normal plantar sensation might to some extent be able to protect such tissue somehow by avoiding full weight bearing during the cycle of walking. However, distant flaps are seldom indicated in leprosy. These patients have feet that lack protective sensation and they need to be able to walk a lot. Distant flaps will not be further described in this chapter with the exception of the medial cross-plantar flap, which I personally have found quite useful.

Local Muscle Flaps

Different local muscle flaps like abductor digiti minimi, abductor hallucis brevis and flexor digiti minimi muscle covered with skin graft are usually of little value since these intrinsic muscles are usually atrophied in the neurologically impaired foot. These flaps will not be further described.

Transposition and Rotation Skin Flaps of the Sole of the Foot

Fascio-cutaneous flaps, i.e. flaps consisting of skin, subcutaneous tissue as well as plantar fascia have been recommended in older leprosy textbooks.⁷

With the exception of the medial plantar island flap, I personally do not have much experience with such flaps. However, the results I have seen done by other surgeons have not been convincing (Fig. 16-7).

In inexperienced hands, these big fasciocutaneous flaps can easily leave the patient in a less favourable situation. However, similar but thinner flaps where the plantar fascia is not included can work well. These are flaps consisting of epidermis, dermis and the specialized fibro-fatty pad overlying the plantar fascia. The dissection is more superficial and technically simpler to do than a fasciocutaneous flap based on an axial vessel, i.e. the medial plantar flap. These superficial flaps must be considered random flaps. The blood supply does not permit an immediate transfer, so they need to be delayed. The flaps should in most cases be laterally based, leaving the donor area with a skin graft in the non-weight bearing medial aspect of the foot. The preferred method of delay might be incision of skin and sub-cutaneous tissue only without undermining the flap, and then re-suturing. After 2 or 3 weeks the flap is transferred into the defect. A split skin graft is applied to the donor area.

Skin Grafting

When an ulcer or defect is due to loss of skin only (e.g. burns), split skin grafting is a useful primary treatment for large and clean granulating ulcers on the sole. In these cases, a layer of plantar fascia and padding remains intact between the graft and the underlying bone. In the non-weight-bearing areas like the instep a split-skin graft can usually be applied successfully even when the pulp consisting of subcutaneous tissue and fascia is missing.

SPECIFIC PROCEDURES

The specific procedures for coverage of ulcer defects on the sole are described below, divided by anatomic region.

Heel Coverage

Small or superficial defects can usually be treated with rest, application of a plaster cast, or simple split skin grafting. In case of a chronic sinus leading down to the bone or the plantar fascia attached to the calcaneus, so-called calcaneal paring is indicated (see Chapter 15). For small deep ulcers a V-Y plasty or delayed cutaneous transposition flap can also work well (See below).

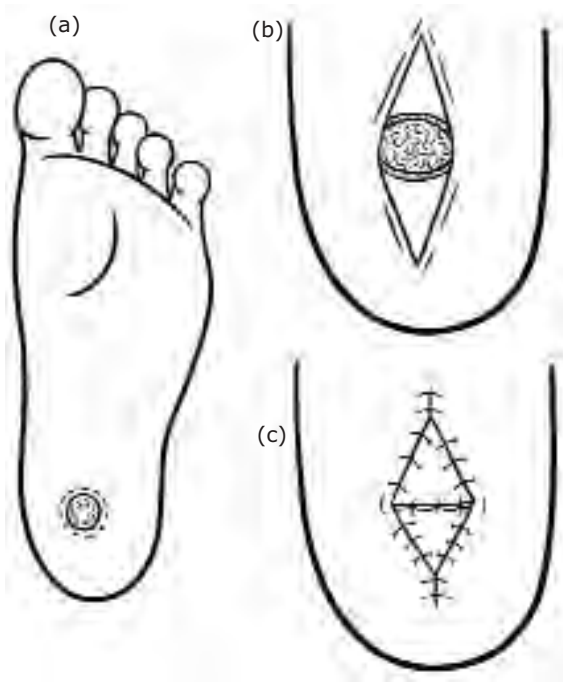


FIGURE 16-1 Small deep heel ulcer covered with opposing V-Y flaps. Because there is absolutely no undermining with the local V-Y flap, its mobility is restricted by underlying tissue and can usually be advanced only 1-1,5 cm. To expand the size of the defect that a single V-Y flap can cover, two opposing V-Y flaps can be designed. The larger the V-Y, the better is the blood supply and the more the flap can be advanced.

The large heel defects, which sometimes present with total loss of soft tissue and bone involvement as well, have too often been an indication for below knee amputation. Large

local fascio-cutaneous transposition flaps recommended in older textbooks might be sufficient to cover smaller defects, but frequently these flaps just do not reach to the area where the tissue is needed the most. Furthermore, the scar left by a poorly designed flap can add an additional problem to the function of the foot.

Laterally based transposition flaps for heel coverage

Alternatively, a laterally based skin flap can be applied (Fig. 16-2).^{3,7}

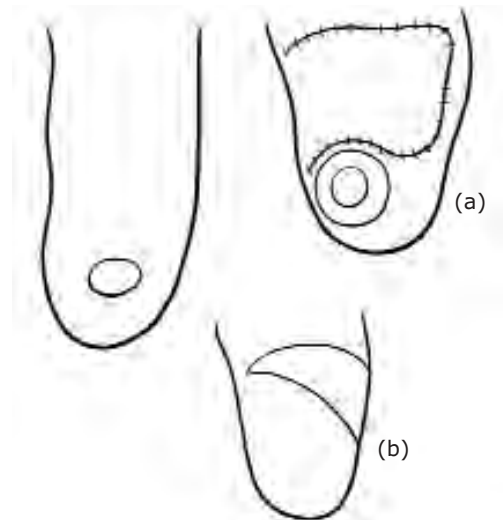


FIGURE 16-2 A relatively small heel defect can be covered with a laterally based transposition flap. **a.** Delay procedure is performed **b.** Surgical correction with excision of ulcer and surrounding scar. The previously delayed flap is transposed into the defect and the donor area is covered with split skin graft.

Medial plantar island flap for heel coverage

This flap has proved to be reliable and extremely useful for heel reconstruction in leprosy (Fig. 16-3).⁵ Hence, it will be described in detail. It should be stressed, however that the dissection is not easy and that some familiarity with more complicated plastic surgical procedures as well as microsurgery is an advantage.

General surgeons with some experience in basic plastic surgery should be able to perform the operation safely after necessary exposure. Learning to utilize this flap is well worth the effort.

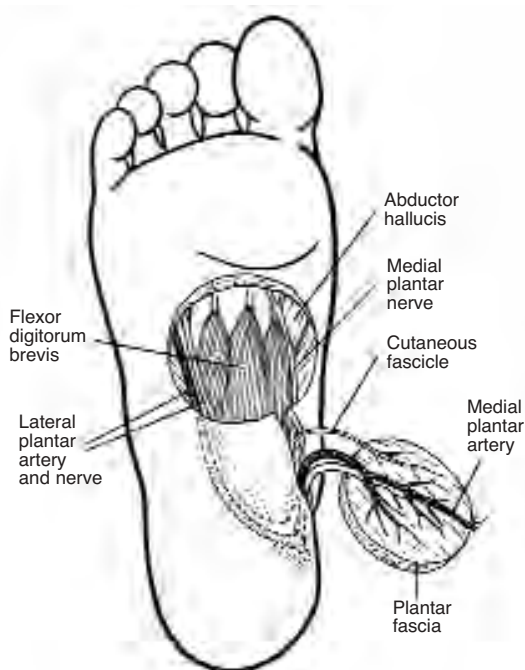


FIGURE 16-3 Anatomy and dissection of the flap.

Indications

This flap is recommended as a standard method for heel reconstruction in most cases where there is major loss of soft tissue. It can be used for recurrent ulcers as well as squamous cell carcinomas of the heel. The posterior tibial artery must be patent. Dorsalis pedis artery or the peroneal artery must also be patent.

Anaesthesia

A spinal or general anaesthesia is usually necessary.

Procedure

The position and route of the posterior tibial artery is marked prior to surgery (Figs. 16-3,

4a). A Doppler can be helpful in this. The patient is placed in a prone position, and a tourniquet is applied. The heel ulcer should be debrided, if necessary debridement could be performed some days prior to the coverage procedure. The ulcer, together with surrounding scar tissue should be excised and the underlying bone should in most cases be trimmed to make sure the bony surface is smooth and healthy. A circular defect is easiest to cover. The flap, which is based on the medial plantar vessels, is planned just proximal to the weight bearing area of the metacarpal heads. The diameter of the flap should correspond to the size of the heel defect and there is no reason to oversize it. A line is drawn from the centre of the flap to the area behind the medial malleolus where the posterior tibial artery was felt before the tourniquet was applied. Then a second line is drawn from the centre of the heel defect to the medial malleolus. The flap is first incised distally down through the subcutaneous fat and the plantar fascia, then in the same manner laterally and medially. Proximally, the incision should be more superficial so as not to destroy the pedicle. Deep intra muscular septa have to be divided in order to raise the flap. The medial plantar nerve can be visualized, and in most cases it can be cut distally and included in the pedicle. This makes the dissection simple and reduces the risk of injuring the vessels. In rare cases, with intact protective sensation of the forefoot, one could consider to retain the nerve in the foot while the cutaneous fibres to the flap itself are peeled off the main nerve. This kind of dissection needs loop magnification. Knowing the direction of the vascular pedicle, a strip of soft tissue about 2 cm wide located between the short muscles of the foot and the plantar fascia will incorporate the vessels. Some deep septa under the pedicle need to be divided. Where the pedicle goes under the abductor hallucis muscle this muscle sometimes needs to be

divided in order to make the pedicle long enough to allow the flap to be transposed smoothly into the heel defect without any tension. It is recommended to make the incision from the heel defect towards the pedicle quite deep, and to do this prior to the dissection of the pedicle itself (Fig. 16-4b). Some undermining of the soft tissue between these incisions will make the flap reach the heel more easily, and one can avoid the most proximal and hazardous dissection of the pedicle. When the pedicle is long enough, the flap is transposed and the tourniquet is released (Fig. 16-4c). After a few minutes of light compression, the bleeding is controlled with a bipolar cautery and a rubber drain is left to drain the pedicle and flap area. The incisions are closed with interrupted 3-0 stitches before the donor area is covered with a split skin graft. A compressing dressing is applied on the donor area with the skin graft while a rather loose well-padded dressing, pos-

sibly with a window for inspection is applied on the heel itself.

After-Care

An adequate prophylactic antibiotic should be given pre- and postoperatively for a few days. The rubber drain is pulled out after 2-3 days, and the whole dressing can be changed after 5-7 days. During this period the patient should have strict bed rest with the foot slightly elevated. Walking without weight bearing is then gradually allowed, and the stitches are removed after 2 weeks time. In most cases full weight bearing is allowed after four to five weeks. Results are shown in Figs. 16-5 and 16-8.

There is a possibility that removal of the plantar fascia weakens the support of the foot and hence predisposes for collapse of the arch later on. In case arch support is considered it is important to wait up to 3 months time in order

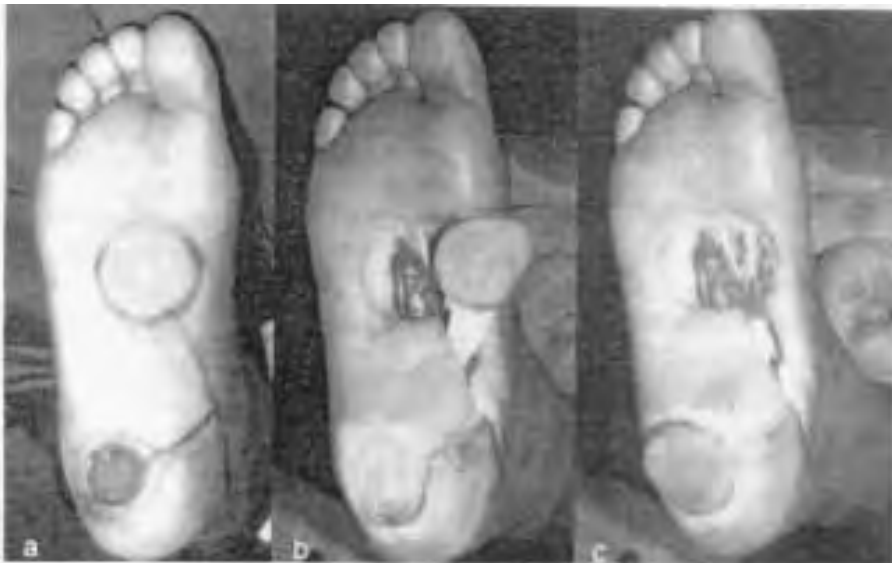

FIGURE 16-4 **a.** Preoperative marking in an 18 year old girl with an ulcer of 2 years duration. Notice how the scar tissue surrounding the ulcer is excised with the ulcer and how the flap is constructed just proximal to the weight-bearing region of the metacarpal heads. A line is drawn from the posterior tibial artery behind the medial malleolus to the centre of the planned flap. Another line is drawn to mark the incision for the tunnel of the pedicle. **b.** The flap consisting of skin, subcutaneous fat, and a thick well-defined plantar fascia is raised on the vascular pedicle. Note the bulk of the pedicle containing the vessels. **c.** The flap is transposed smoothly to the defect without tension or kinking.

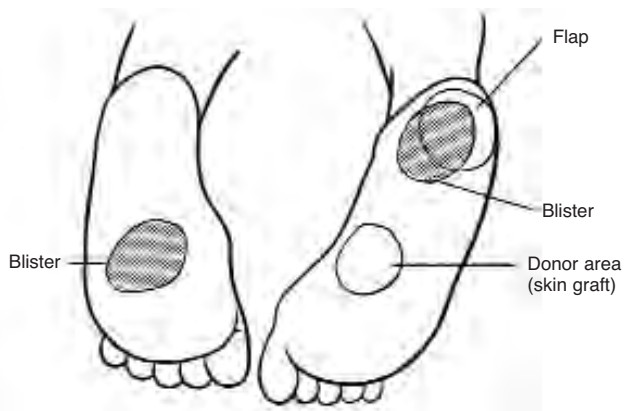
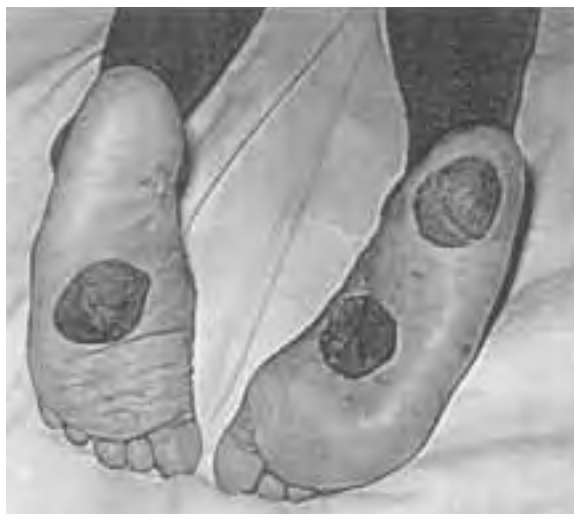

FIGURE 16-5 A 33 year old man operated for an ulcer of the right heel 4 months previously. His left foot was “boatshaped” because of collapse of the longitudinal arch. A 10 km long walk resulted in haemorrhagic blisters (dark area of left midfoot and right heel). Notice how the blister of the right heel is affecting the flap and surrounding tissue equally, indicating that the quality of the flap is similar to that of the native soft tissue of the heel.

to let the split skin graft of the donor area gain sufficient stability and strength to take the pressure from the inlay device. The defect left by the removal of subcutaneous tissue will have filled in by that time.

Cross-Foot Flap for heel coverage

In case the instep of the same foot is not suitable for a flap harvest, it is possible to raise the medial plantar flap from the contra lateral foot (Fig. 16-7). An external osteo-fixation between the tibias as well as a K-wire between the two calcaneal bones will keep the legs in a stable position until the pedicle is safely divided after two weeks. Alternatively, plastering can be used to hold the position but is difficult to maintain.

Midfoot Coverage

Defects on the medial aspect of the plantar surface are non-weight bearing and are best treated with skin grafts. If there is an underlying

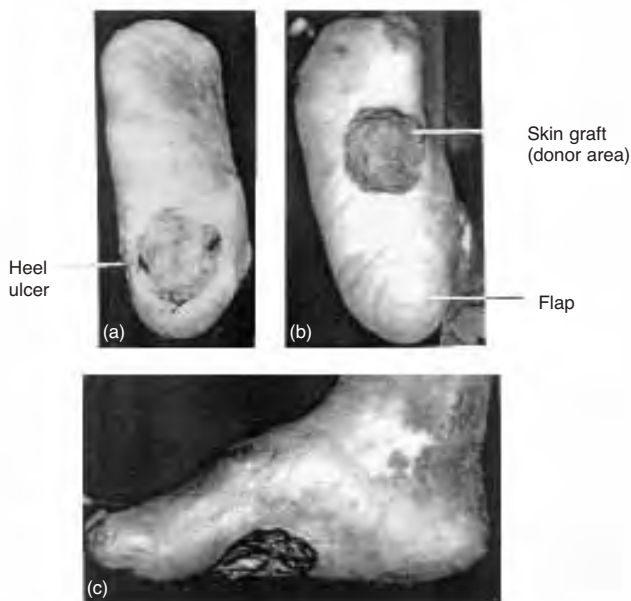


FIGURE 16-6 a. Extensive heel ulcer with total loss of soft tissue of 8 years duration in a 48 year old man. **b.** 8 months after reconstruction the heel looks normal with an excellent result including good stability.

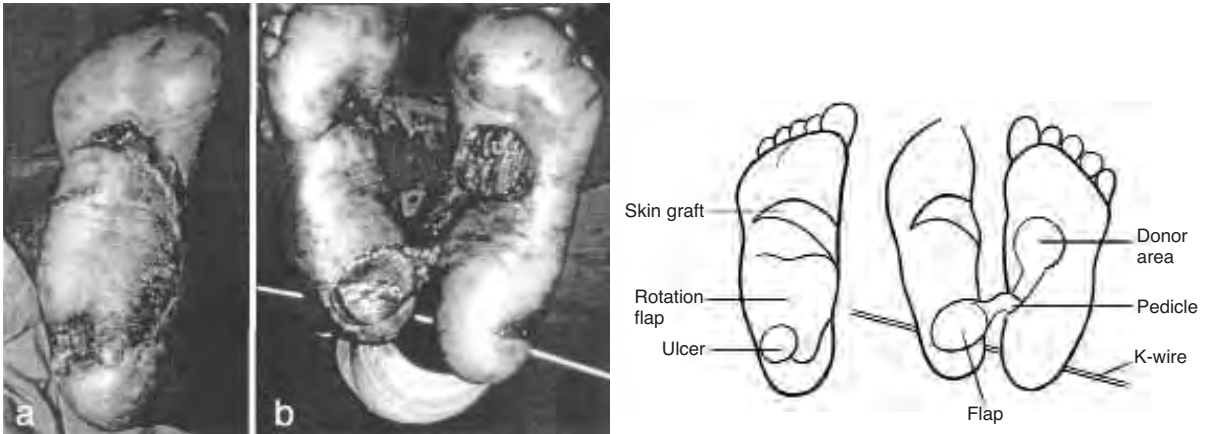


FIGURE 16-7 **a.** The plantar area in a 40 year old woman who had a huge laterally based fasciocutaneous transposition flap raised 3 years previously. Notice new ulceration of the heel area. **b.** Operative picture showing adequate length of the vascular pedicle reaching from one instep to the opposite heel. External osteofixation between the two tibias and a K-wire through the calcaneal bones kept the legs in a stable position until the pedicle was safely divided two weeks later.

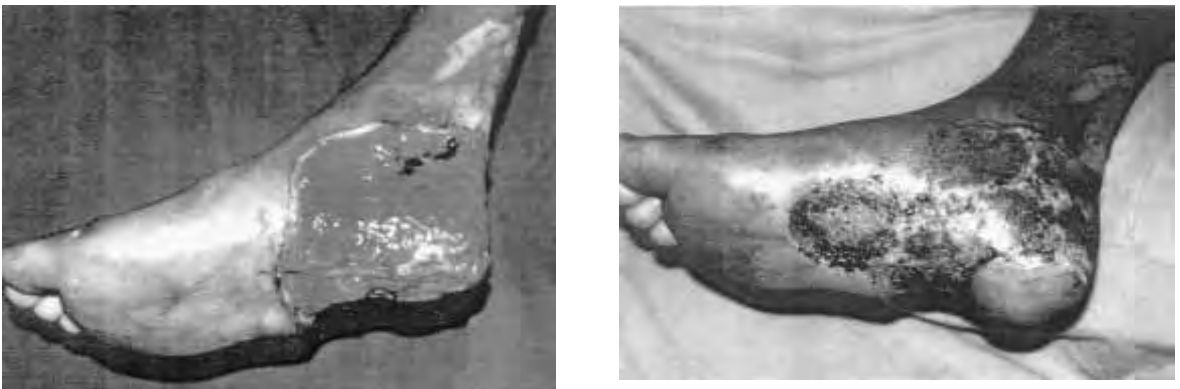

FIGURE 16-8 Pre- and postoperative pictures in case of an extensive avulsion injury in 25 years old non-leprosy patient. The weigh-bearing area of the heel is covered with an island flap from an intact distal instep. The donor area as well as the remaining raw area is covered with split-skin.

bone causing an existing midfoot ulcer, as usually occurs with a collapsed Charcot foot, the excess bone can be shaved via a lateral or medial approach or sometimes directly through the ulcer during debridement. The ulcer can be either allowed to heal by secondary intention or addressed depending on its size. For small defects, a V-Y flap can be useful, while for larger defects large medially or laterally based delayed random flaps can work well (See type of flaps).

Once healed, the patient with a Charcot foot has to be considered for a possible mid/hind foot fusion so that the breakdown will have less chance of recurring.

Forefoot Coverage

For small ulcers over the MTP joint without bone involvement a pressure point reduction procedure (see Chapter 15) is usually sufficient for the ulcer to heal by secondary intention. Small deep forefoot ulcers without an obvious

bony prominence can also be covered with a local flap: a filleted toe flap, (Fig. 16-9) a toe island flap (Fig. 16-10), a V-Y flap² (6) or a larger rotation flap (Fig. 16-11).

Using soft tissue from a toe:

Indication: Small and deep recurrent ulcers of the forefoot, usually under the metacarpal heads.

In leprosy, functionless toes, subluxated appendages with their own risk of friction ulceration can serve the foot instead of being a troublesome liability. Generally, the soft tissue of the toe is used in the flap, discarding the skeleton. Alternatively, if the toe has a normal

The toe is incised dorsally and the soft tissue is dissected from the skeleton, visualizing the neurovascular bundles. The toe skeleton can now be excised. The metacarpal head should be trimmed or removed, depending on the condition of the forefoot. The neurovascular bundles are then mobilized, dividing the transverse ligament. After freeing the skin, the flap is hinged into the defect. Excess toe skin might need to be resected.^{4,8}

Toe island flap (Digital Artery Island Flap (Fig. 16-10)

Based on one of the neurovascular pedicles this flap can close small forefoot ulcers.

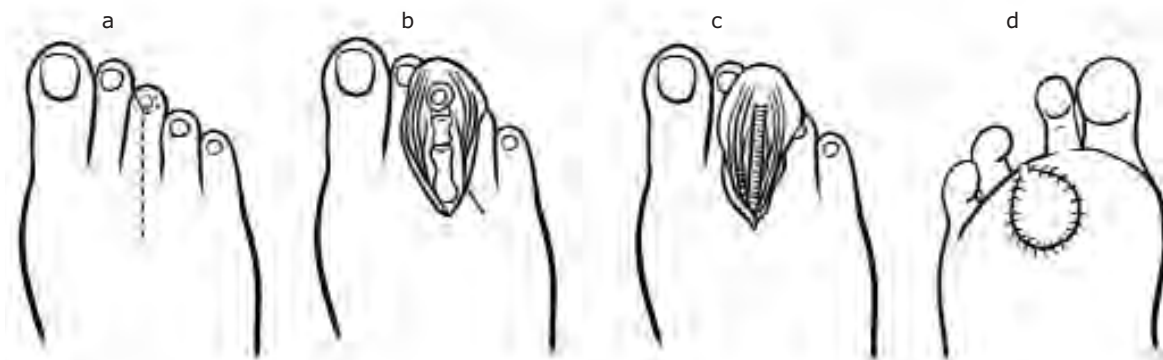


FIGURE 16-9 Toe island flap (Digital Artery Island Flap) **a, b.** Dorsal incision with excision of nail **c.** Excision of bone **d.** Final result.

shape and size, one-half of the toe skin based on one neurovascular bundle could be used, grafting the resulting defect on the toe. For replacement of a defect in the metacarpal head area the soft tissue of the toe might be hinged at the level of the transverse plantar ligament, although it can be hinged as far back as the plantar arch if dissection deep to the toe flexors is involved.

Filleted Toe Flap (Fig. 16-9)

Technique: The plantar ulcer with surrounding scar is excised, leaving edges of healthy tissue.

Technique: The flap consisting of skin and subcutaneous tissue is designed on the side of the toe avoiding the nailbed and including only part of the plantar area of the toe. The incision is extended through the plantar pad of the forefoot, and the neurovascular bundle that lies on the side of the flexor tendon is mobilised. As for the filleting toe flap, the transverse ligament must be divided. When the pedicle has sufficient length, a subcutaneous tunnel is created to the ulcer area; the island flap is transposed and sutured. The donor area of the toe is covered with a skin graft.

V-Y Plasty for forefoot coverage

See V-Y Plasty for coverage in the heel area. (Fig. 16-1) The principle as well as the limitations is much the same in the metacarpal areas.

Laterally based Transposition Flap for forefoot coverage (Fig. 16-11).

Indications: Recurrent ulcers of the medial and central forefoot.

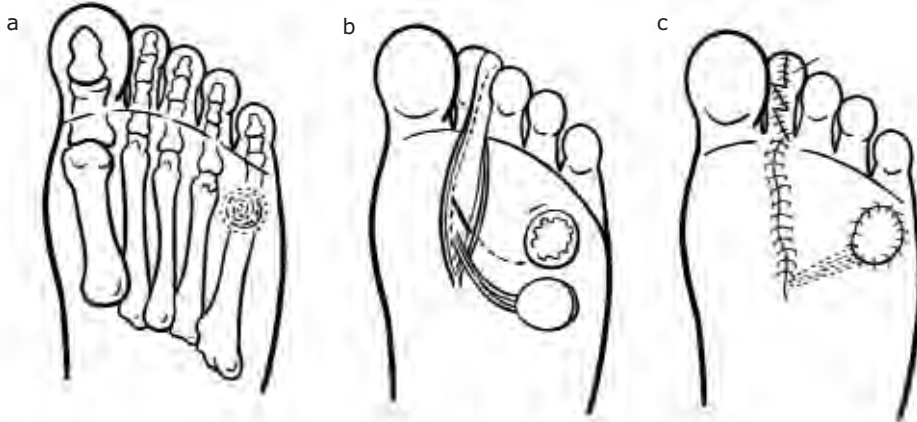


FIGURE 16-10 Digital artery island flap. **a.** Site of ulcer under 5th metatarsal head. **b.** flap raised from site of toe based on neurovascular pedicle. **c.** Flap insert, skin graft sutured over defect.

Reversed medial plantar island flap for forefoot coverage

A modification of the medial plantar flap is also described to cover the distal weight bearing area of the foot. The standard medial plantar flap described above derives its blood supply from the medial plantar artery, a terminal branch from the posterior tibial artery. The modified flap gets its blood supply from a reversed flow in the lateral plantar artery and vein. This flap is probably most useful after trauma and tumour resection, but occasionally the neuropathic foot might present a huge ulcer or unstable scar on the forefoot area where this flap might be used. Technically it is more complicated to raise the reversed flap than the standard flap, and the surgeon should be familiar with the latter before trying the more complicated reversed one. The operation will not be described in detail in this chapter, but interested readers might find out more about this flap described by Martin and co-workers.⁸

Technique: See discussion above regarding rotation flaps in the foot. A laterally based flap starting just posterior to the ulcer is cut down to fascia and sutured. Two weeks later the ulcer with surrounding scar is excised, the flap is raised in a plane just superficial to fascia. The flap is then rotated into position and sutured. The defect on the non weight-bearing instep is skin grafted. Post-operative care is as for the medial plantar artery flap.³

Summary

In the neurologically impaired foot pressure ulcers are common. Pressure point reduction must always be addressed. Most ulcers, perhaps with the exception of huge heel ulcers, will heal by secondary intention if treated conservatively in the right manner. However, conservative treatment can be very time consuming and might sometimes leave unstable scars. For those with recurrent ulcers, the time taken off work to heal these ulcers can be economi-

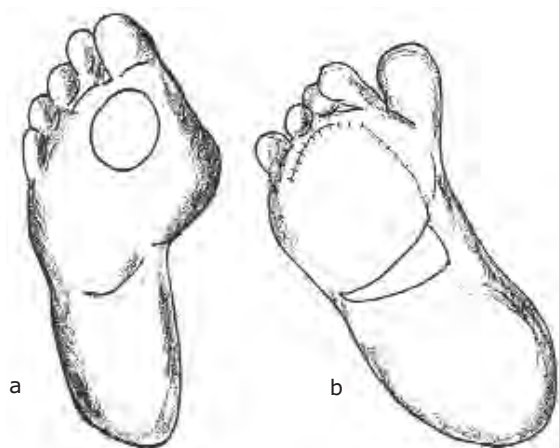

FIGURE 16-11 Lateterally based fascio-cutaneous flap. **a.** large medial forefoot ulcer **b.** Flap raised and sutured into defect with skin graft to donor area.

cally debilitating. Skin grafting and flap coverage can be rewarding in selected cases. Follow up with proper footwear is of uttermost importance.

Soft tissue coverage can only occur when all signs of infection have resolved and the foot has an adequate blood supply.

REFERENCES

1. Attinger C E: Use of Soft Tissue Techniques for Salvage of the Diabetic Foot. pp 323-366. Kominsky. Medical and surgical management of the diabetic foot. St Louis: Mosby Year Book, 1994
2. Colen LB, Repogle SL, Mathes SJ: The V-Y plantar flap for reconstruction of the forefoot, *Plast reconstr Surg* 81:220, 1988
3. Curtin JW: Transposition and Rotation Skin Flaps of the Sole of the Foot. pp 1815-1819. In Grabb's Encyclopaedia of Flaps, Volume three, second edition. Lippincott-Raven, 1998
4. Emmet AJJ: The filleted toe flap. *Br J Plast Surg* 29:19, 1976
5. Gravem PE: Heel ulcer in leprosy treated with fasciocutaneous island flap from the instep of the sole. *Scand J Plast Reconstr Hand Surg* 25: 155-60, 1991
6. Harrison DH, Morgan BDG: The instep island flap to resurface plantar defects. *Br J Plast Surg* 34: 315, 1981
7. Lennox WM: Surgical treatment of chronic deformities of the anesthetic foot. pp 350-373. In McDowell F and Enna CD (eds): *Surgical Rehabilitation in Leprosy*. The Williams & Wilkins Company, Baltimore, 1974
8. Martin, D. Gorowitz, B. Peres, J.M. and Baudet, J: Medial plantar artery flap. pp 1848-1850. Grabb's Encyclopaedia of Flaps, Volume three, second edition. Lippincott-Raven, 1998

Foot Orthotic Therapy

• H. CROSS

“There is hope of saving the feet of leprosy patients only when it is widely recognised that the whole problem is really one of mechanics, not of medicine. The advice and help of the physiotherapist, the social worker and the shoe maker are likely to be of more significance than the medicine of the physician or the knife of the surgeon.” (Brand, 1989)⁴

INTRODUCTION

Many of the principles underlying footwear design for anaesthetic feet have remained essentially unchanged since the early 1960s when pioneers such as Bauman, Brand, Price and Ross began to accentuate the importance of footwear provision.^{1,4,22,24,27,28} With utmost respect to those who have contributed so much to our current understanding of foot pathology, this chapter is offered as a further contribution. The chapter does not, however, provide the definitive answers. The early pioneers used physics to explain why people affected by leprosy developed ulcers. It may be that in the twenty-first century, physics will not be enough. We will need to find psychosocial answers to explain why people affected by leprosy are still developing ulcers. Footwear affordability with client acceptability and compliance have perhaps become the most important factors to consider if the challenge of plantar ulceration is to be met. Any attempt to provide appropriate footwear and appliances will be confounded if these crucial issues are not respected.

PHYSICS AND FUNCTION

Price recommended that all feet compromised by scarring should be fitted with a rigid soled sandal with a soft insole.²⁴ He designed a wooden sandal with a soft insole to meet these criteria and suggested that:

“The rigid sole forestalls deep damage between soft tissues and the bony skeleton of the plantar region. The soft insole forestalls damage caused by friction between the skin surface and the immediate points of contact.”

Price's assumption that soft material would forestall damage due to friction was at best only partially correct. The effect of cushioning is to reduce force by decreasing the acceleration quotient of the “mass x acceleration” equation describing force. The suggestion that the “rigid sole forestalls deep damage between soft tissues and the bony skeleton of the plantar region” finds some support because the rigid sole he designed incorporated a rocker effect beneath the metatarsal heads.

Translational friction is an essential component of grip and is proportional to the product of the normal force and a coefficient of friction dependent on the properties of two involved surfaces. It may be described as a force acting to prevent relative sliding between two contacting surfaces. Friction acts to stop the moving foot and as such it is essential if man is to walk. If the internal momentum between bone and soft tissue continues to excess however, shearing stress and tissue fatigue can be a result.²⁵

Many have sought to address the problem of shearing stress by immobilising the foot

using rigid soled footwear. Although the concept of immobilisation to prevent shearing stress appears sound, it can bear a high functional cost.

Dorsiflexion of the toes stabilises the forefoot and thereby facilitates effective ankle plantarflexion at propulsion. When the toes dorsiflex the skin is drawn distally to permit unimpaired motion. This action results in horizontal shear between skin and metatarsal heads which is greatly exacerbated by the posterior thrusting of the skeleton to achieve acceleration for locomotion. It was reasoned, therefore, that by preventing toe dorsiflexion shearing stress in the tissues between the metatarsal heads and the skin would be reduced.

The anatomy of the normal footpad, however, is structured to accommodate shear.⁵ Further mechanisms permit an element of sliding between soft tissue structures and bones, these include bursae and synovium encapsulated joints. It is only if the integrity of these structures is challenged by excessive demand that they will demonstrate fatigue. Alternatively if the structures have been damaged and scarring has resulted in the adhesion of skin and fascia, the functional capacity of these features may be markedly reduced. By eliminating the requirement to dorsiflex the toes, therefore, there will be a reduction in stress in the tissues beneath the metatarsal heads. Although eliminating these sagittal movements may be advantageous, the potential problems associated with uncontrolled frontal and transverse plane movements should also be considered

FOOTWEAR

Rocker Shoes

Bauman et al. conducted a comprehensive study of rocker shoes for leprosy patients.¹ Their study focused on kinetic effects and assumed that changes in pressure distribution

would alter a predisposition for the foot to ulcerate. On the basis of their findings they suggested that the angle of rocker, the antero-posterior position of the rocker axis and the orientation of the rocker axis with the shoe were key criteria. What arises from reviewing the literature however, is that there is no consensus relating to rocker shoes on these criteria.^{21,30,31}

A reduction in pressure under the medial and central metatarsal heads (MTHs) with a rocker positioned behind the MTHs was a recurrent finding.^{6,7,21,30,31} However, a comparable reduction in pressure on the lateral forefoot has not been reported. Some investigators have recorded an increase in pressure under the fifth MTH.³⁰ The elevated pressure, or insignificant reductions in pressure on the fifth MTH, were probably due to rockers being positioned nearer the fifth MTH which lies in a proximal position relative to other MTHs (author's opinion).

Pollard et al. were able to report that an effect of rocker bottom shoes is the reduction of shearing stress.²³ Significant reductions in longitudinal shear were demonstrated when a shoe, incorporating a "deep rocker" behind the MTHs was compared with other types of footwear. Increased heel loading and force impulse, the product of force and the duration of the application of force, are widely reported. Such findings suggest that rockers are contraindicated for individuals with a history of heel ulcers.

The height of the rocker is a critical factor. If the anterior edge of the rigid shoe makes ground contact at propulsion there will be considerable force applied to the forefoot. This effect is the result of an alteration in the order of leverage with the distal displacement of the axis of motion. However, a greater risk may prevail for the midfoot due to the loss of toe dorsiflexion. If the distal edge of the footwear does make ground contact, the lever arm that normally extends to dorsiflex the toes at the

MPJs is extended to demand dorsiflexion at the ankle which, during propulsion, is being used to apply a plantarflexion thrust. The effect of the opposing forces of dorsiflexion and plantarflexion is that propulsive plantarflexion is jammed. A large dorsiflexion moment is created around the ankle. As the ankle reaches the limit of its range of motion, force is translated forward into the subtalar and midtarsal joints. The talar navicular articulation will present the first occasion of least resistance and excessive opposing forces may cause the dorsal edges of the opposing bones to impinge on each other thereby potentiating trauma. This may be a significant consideration for neurologically impaired feet, vulnerable to neuropathic bone disorganisation.

Further rationale for the use of rocker shoes was that the rigidity and alternative geometry of the shoe would alter gait to the benefit of the injured foot. Schaff and Cavanagh demonstrated this effect by recording that all subjects wearing rocker shoes in their study took shorter steps (reduced by 8 cm) and increased rate of cadence by six steps a minute.³⁰ Zhu et al. reported findings that support Brand's hypothesis that a shuffling gait would reduce peak pressure.³³ They later presented evidence to indicate that an increased cadence was associated with increases in peak pressure.³⁴

There can be little doubt that rocker shoes may significantly improve the prospects for foot salvage. The cost of producing and supplying effective rocker shoes, however, is prohibitive. Furthermore, in India distinctive footwear is a major stigmatising agent and patients are understandably unwilling to pay for footwear meeting such low patient acceptance.

SANDAL DESIGN

Enna presented a sandal designed for leprosy impaired patients in America.¹⁰ He sought to

produce a sandal incorporating a moulded polyethylene insole, supported by a mixture of sawdust and latex on a neoprene crepe sole. This approach could be useful for patients with an a-propulsive gait, but it may be contra-indicated for more normally functioning feet. The foot is a dynamic structure, it shortens and lengthens during the normal stance phase of the gait cycle. Unless the foot is immobilised with a rigid sole incorporating a rocker, a close fitting moulded innersole could be counterproductive. Enna's choice of expanded polyethylene is not appropriate unless resources permit frequent change because the material compresses within a relatively short period.

Patil et al. also based their recommendations on static studies.²² However, their recommendations were that microcellular rubber, of varying degree shore, should be used as components to form a composite sandal insole. Their recommendations are based on findings relating to one atypical subject and whilst demonstrating the requirement to address individual needs their recommendations may not be applicable for the general population of leprosy sufferers.

Attempting to address the problem of stigmatising footwear, Antia designed an extruded plastic sandal which was similar in appearance to sandals obtainable in local markets throughout India. This sandal incorporated an upper to hide moderate deformities, a heel counter and a steel shank beneath an 8mm, 18 shore EVA sponge. These sandals were evaluated by Kulkarni et al. who used Harris mats to demonstrate reduced loading.¹⁸ They also reported problems associated with the dorsum of the foot where the plastic had caused cuts. There were further problems with the fittings on the shoe (buckles snapped off).

The rationale for introducing a steel shank is to limit dorsiflexion at the metatarsophalangeal joints (MPJs). The potential for damaging effects on the midfoot if toe dorsiflexion is

prevented is presented above (see Physics and Function).

THE FOOT ORTHOSIS AS AN APPROACH TO MECHANICAL MALFUNCTION AND ITS EFFECTS

The general aim of a foot orthosis is that it should intervene to attenuate the punishing consequences of abnormal foot structure or function. More specific aims will depend on the nature of the underlying problem. The action of some orthoses will be to perform as a substitute for anatomical inadequacy whilst others will aim to alter kinematic function or the effects thereof. More specific aims include:

1. The correction of phasic joint kinematics by controlling the extent of subtalar pronation.
2. The redirection and redistribution of force.
3. The accommodation of foot structure to facilitate optimum foot function.
4. The attenuation of effects of uncontrolled subtalar pronation.
5. The distribution of weight over an increased area of the foot.
6. The support and palliation of vulnerable areas of the foot
7. The deflection of pressure from a vulnerable area.
8. Cushioning to reduce impact.

Investigators have studied a variety of variables considered to be affected by foot orthoses. Landorf and Keenan have presented a comprehensive literature review of recent studies which the author recommends.¹³

The Functional Orthosis

The term “functional” when used in this context usually refers to an orthotic device that restricts subtalar pronation. The aim of a functional orthosis is to improve the prospects for

the foot to achieve the desirable objective of reaching mid stance with the subtalar joint approximately neutral (i.e. neither pronated nor supinated). If this objective is reached it is reasoned that the foot will be ideally prepared, kinematically, for the demands of the propulsive phase of stance.¹⁷

An appropriately angled wedge beneath the heel effectively brings the supporting surface into contact with the inverted position of the calcaneus at heel strike. The angle of the wedge is calculated by measuring the angle between the supporting surface and the calcaneus when the subtalar joint is in its neutral position.³ A response to this approach is that the subtalar joint will pronate but not to excess. The angle of the wedge may be increased to accommodate ligamentous laxity which would exacerbate the tendency of the subtalar joint to pronate.²⁶

Orthoses that do restrict or attenuate the effects of subtalar pronation are likely to affect the subsequent function of the foot. Such devices are, therefore, “functional” in their action. A term commonly used for orthoses that are not prescribed principally to alter foot function is “accommodative”. The term has passive connotations and does not project the potential for such devices which can in fact initiate dynamic effects.

Individuality dictates that orthoses require consideration of peculiar specifications. Orthoses are prescribed on consideration of a combination of criteria. The prescription will be based primarily on a subject’s foot structure and gait. Other physiological considerations will be arterial supply, venous return and neurological status. An assessment of intellect and psychosocial factors is also required. There are basic components that can be incorporated in the manufacture of an orthosis. These are commonly used in combinations, however, each component is specific and may be applied in isolation, where appropriate. The efficacy of

foot appliances as an adjunct to the treatment of plantar ulceration in leprosy has been investigated.^{8,9}

Note: All foot orthoses described in this chapter are ideally constructed using micro cellular rubber (MCR) but can be made using other materials including ethyl vinyl acetate (EVA) or Poron.

The Tarsal Platform

The tarsal platform is designed to extend from the anterior edge of the heel to a line immediately proximal to the metatarsal formula (the arc in which an individual's metatarsal heads lie in the transverse plane) where the full thickness of the material (4 to 5 mm) is bevelled to accommodate the metatarsal heads (Fig. 17-1).

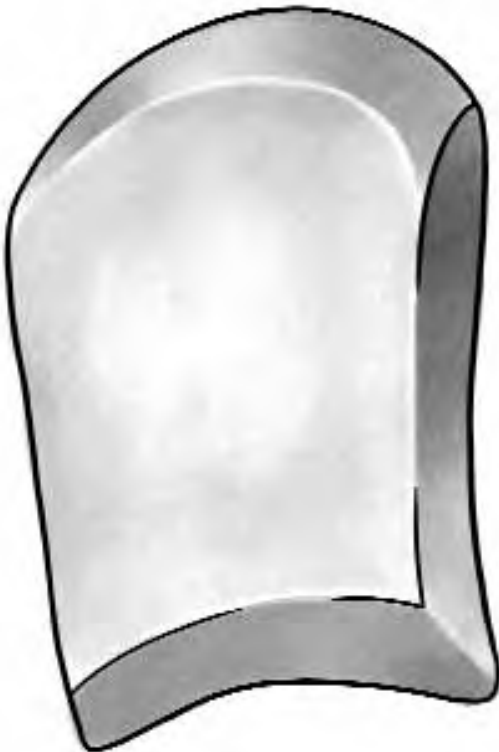


FIGURE 17-1 Tarsal Platform— **Action:** Reduce pressure and the duration of pressure applied to metatarsal heads; Loads metatarsal shafts; Counters STJ supinatory effects.
Indications: pressure lesions affecting a rigid functioning foot (as with STJ supination).

The posterior edge is shaped to the heel and bevelled to a width of approximately 1 cm. As a platform of firm material, it enlarges the weight bearing area of the foot and relieves the loading on the heel and metatarsal heads. Its primary function is to bring the lateral border of the foot into contact with the supporting surface. In so doing it imposes a slight evertory force on the foot. As a basic structure, it is indicated for pes cavus feet which exhibit excessive metatarsal loading and lateral instability but is contra indicated for feet with fixed varus abnormalities.³² The author suggests that it should not be used where feet demonstrate grossly abnormal lateral loading (as in foot drop). The tarsal platform is the base for a number of modifications designed to meet individual requirements.

The Tarsal Cradle

This is an extension of the tarsal platform to include a medial arch support with a flanged extension (Fig. 17-2). The structure is modelled to fill the concavity of the medial longitudinal arch thereby maintaining the architecture of the arch as it resists the effects of abnormal (late or excessive) subtalar pronation.²⁹ The author recommends that it should extend medially, as a flange, to cover the sustentaculum tali, the talar head and the tuberosity of the navicular. From its highest point, at the tuberosity of the navicular, it should slope inferiorly to the base of the first metatarsal head.

Note: Whether an arch support is used as a component of a tarsal cradle or independently, the structure of the support is crucial to its function and acceptability.

A well-designed tarsal cradle will support both the medial and lateral borders and present resistance to hypermobility of the foot. When the calcaneus everts it causes an axial rotation

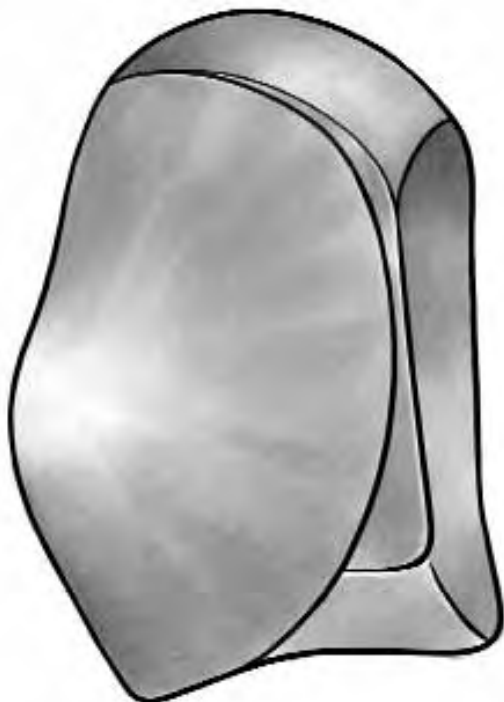

FIGURE 17-2 Tarsal cradle— **Action:** Redistributes forces; Stabilises the foot against the affects of STJ pronation; Augments first ray function.
Indications: Feet at risk of the affects of aphasic STJ pronation.

of the cuboid which destabilises the lateral column and consequently causes hypermobility of the fourth and fifth metatarsals.¹² The tarsal platform component supports the medial, plantar and posterior process of the cuboid which underlaps the calcaneus. This support adds resistance to calcaneal eversion and in so doing enhances the stability of the lateral column.²⁰ In a similar fashion, support beneath the tuberosity of the navicular and sustentaculum tali should resist the adduction and plantarflexion of the talus and the eversion of the calcaneus respectively. These effects should contribute to the stability of the medial column and the foot in general.

The salient objective of the tarsal cradle is to facilitate efficient functioning of the first ray.

Assuming normal phasic activity, as the STJ starts to supinate (after heel strike), the tarsus inverts and the second metatarsal follows to assume an inversion tilt. Responding to ground reaction force the lateral metatarsals will dorsiflex to the extent allowed by individual tarsometatarsal connections. This is usually sufficient to allow the metatarsal heads to lie in a common transverse plane.¹²

As the lateral metatarsals dorsiflex in response to ground reaction, the medial side of the foot remains tilted in inversion. To attain a plantigrade attitude and stabilise the foot for propulsion the first ray must plantarflex. The first ray has a triplane axis. As the first ray plantarflexes therefore, it also everts. The torsional twist around the second metatarsal head contributes to a tightening of the support structures of the medial arch.¹⁹ The medial arch is simultaneously heightened by the plantarflexion of the first ray and extension of the digits.¹⁵ Whereas the dorsiflexion of the lateral rays is principally a passive response to ground reaction, the plantarflexion of the first ray is dynamic. Efficient first ray function is dependent on a number of structural and functional variables.²⁶

If the STJ is supinated the first cuneiform and the base of the first metatarsal are elevated relative to the cuboid. Using the stabilised cuboid as a pulley, the plantar direction force of peroneus longus is enhanced by the increased angle of approach to its insertion. This mechanical advantage allows peroneus longus to stabilise the first ray at its base. Its function is also to synergise with the actions of abductor hallucis and flexor hallucis to bring the ray into plantarflexion. In so doing maximal benefit is achieved from compressional forces to stabilise the medial kinematic chain in preparation for propulsion.^{12,26}

If the medial column is destabilised due to subtalar pronation the first ray will dorsiflex in response to ground reaction. As a consequence

the angle of approach of peroneus longus will be reduced. Having lost mechanical advantage peroneus longus will be unable to effect adequate plantarflexion of the ray and the integrity of this crucial mechanism is compromised. The second or third metatarsal heads are exposed to excessive compressional and shearing stress.²⁶

Facilitating first ray function is a fundamental aim if forefoot integrity is to be maintained.¹⁵ By supporting the structures that maintain the optimal height of the arch it is reasoned that the dynamic features of first ray function will be augmented. This may be the most important function of the tarsal cradle.

The author suggests that if the tarsal cradle is extended medially and posteriorly to include a partial heel meniscus this will benefit the

objective of subtalar pronation control. By including a medial wedge a supinatory moment will oppose the pronatory moment around the subtalar axis (Fig. 17-4). This effect will inhibit, if not prevent, the eversion of the calcaneus.^{11,17} Other modifications can be made to address individual specifications.

Anti Pronatory Orthosis

Whereas the tarsal cradle can be useful as a therapeutic appliance (i.e. used where there is frank ulceration or other trauma) an anti pronatory orthosis can be prescribed as a prophylactic appliance. The appliance described here is known by various different names some of the more colourful of which reflect its shape (eg. Cobra pad, Hathi pad). The appliance comprises a combination of a medial arch sup-

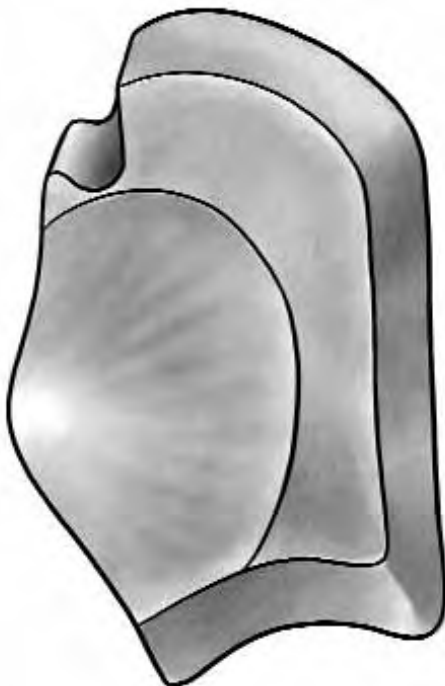


FIGURE 17-3 Combination Tarsal cradle with PMP- **Action:** Stabilises the foot against the affects of STJ pronation; Deflects pressure from an injured metatarsal head; Loads metatarsal shafts and unaffected metatarsal heads.
Indications: Lesions affecting a hypermobile foot (as with STJ pronation)

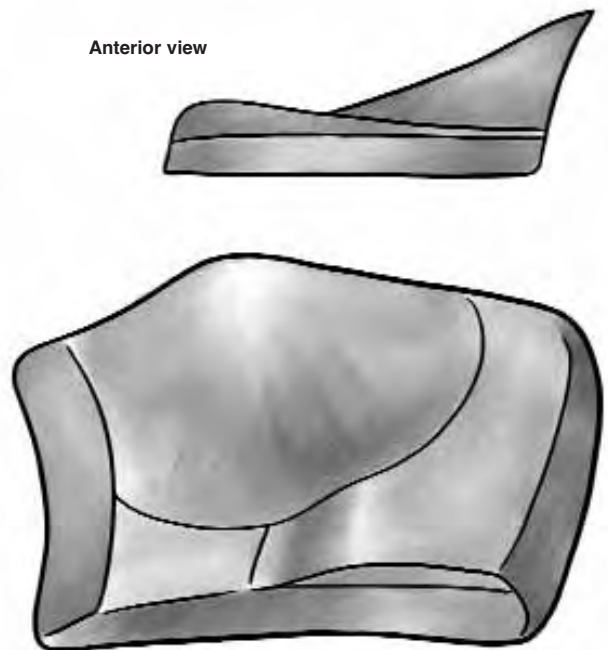


FIGURE 17-4 Combination Tarsal Cradle and Medial Wedge- **Action:** Accommodates forefoot valgus deformity; Stabilises the foot against the affects of STJ pronation.
Indications: Forefoot Valgus.

port with a heel meniscus (Fig. 17-5). The heel meniscus is designed such that the medial aspect has a wedge effect to limit the extent of calcaneal eversion. The lateral aspect (which extends to the styloid process of the fifth metatarsal) increases the weight bearing area of the heel and contributes to the stability of the foot.

As a general principle, where it is found that patients present with aphasic pronation an anti pronatory appliance should be offered to promote optimal foot function and thereby reduce the risk of insidious trauma. It should also be considered as a post Tibialis Posterior Transfer intervention. Electromyographic stud-

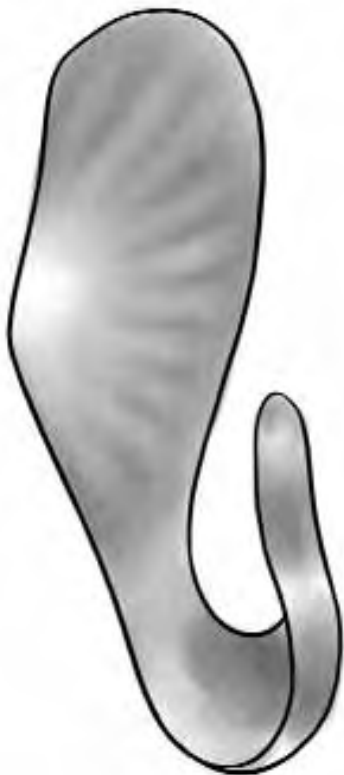

FIGURE 17-5 Anti-pronatory appliance— **Action:** Resists the eversion of the calcaneus; Stabilises the foot against the affects of pronation; Enhances first ray function.

Indications: Feet demonstrating excessive STJ pronation.

ies have demonstrated that tibialis posterior fires at heel strike.²⁶ The timing of activity and insertions of the tendon suggest that principle actions of the muscle are to prevent excessive STJ pronation and to restrain the foot against the effects of pronatory force. The removal of the tendon from its insertion therefore leaves the foot without this crucial protective mechanism. An antipronatory appliance as described here will compensate, to some extent, for the loss of normal tibialis posterior action.

Note: Whilst TPT surgery should be conducted to address the gross insult of foot drop (a sagittal plane problem) the effect of muscle transfer on frontal plane action should not be ignored. Although less likely to lead to acute trauma the affects of hyper pronation after TPT surgery are an insidious threat to the integrity of the foot. Soft tissues are challenged but there may also be a significant threat to joints. If the STJ is pronated at the propulsive phase of gait the tarsal joints will be more vulnerable to trauma because the articulating surfaces of opposing bones will not be congruent. Loss of joint congruency favours rotational forces rather than stability. Rotational forces destabilise the joints and increase the risk of fracture. Furthermore loss of congruency can lead to foci of force being applied to small areas of an articulating surface which can cause joint destruction (as in osteochondritis dissecans).

The Metatarsal Rocker

The metatarsal rocker is shaped to conform to the metatarsal formula and is situated immediately proximal to the metatarsal heads.²⁰ The author suggests that if a foot has been damaged such that the osseous structures of the forefoot no longer conform to normality, a metatarsal rocker can be shaped to correspond with the tread line of the foot. With such a foot the rocker is positioned immediately proximal to the tread line. The bar can be incorporated

onto a tarsal platform or a tarsal cradle (Fig. 17-6). It can also be used independently of other options.

The author suggests that the action of the metatarsal rocker is that it should shift the tread line posteriorly, away from a vulnerable or traumatised area, to a less vulnerable area of the foot. In so doing it will mimic the pivotal role of the metatarsal heads. It must, therefore, be constructed to an optimal height to allow clearance of the vulnerable area. These devices may be particularly useful for feet that no longer demonstrate a normal heel toe gait.

The Plantar Metatarsal Pad

The full thickness of a plantar metatarsal pad (PMP) extends from beneath the heads of the three central metatarsals to two thirds of the length of the metatarsal shafts (Fig. 17-7). The anterior edge conforms to the metatarsal formula. It is bevelled from the metatarsal heads

to extend beneath the anterior plantar fat pad, to a distance immediately proximal to the webbing of the toes. The lateral and medial edges are also bevelled from the area beneath the second and fourth metatarsals to the medial and lateral aspects of the forefoot respectively. A 1 cm bevel extends from the posterior limit of the full thickness of the pad. The effect is, that on weight bearing, the central metatarsals are elevated. The load on the metatarsal heads is relieved due to the combination of elevation and an increased area of weight bearing.²

Where feet are compromised by the chronic fixation, dislocation or subluxation of the metatarsophalangeal joints, the PMP is applied to palliate the metatarsal heads by redistributing the load. Where a foot presents with mobile claw toes or retracted toes the metatarsals are forcibly plantarflexed.²⁶ In the action of elevating the metatarsals, the PMP assists by correcting the alignment of the metatarsal heads.

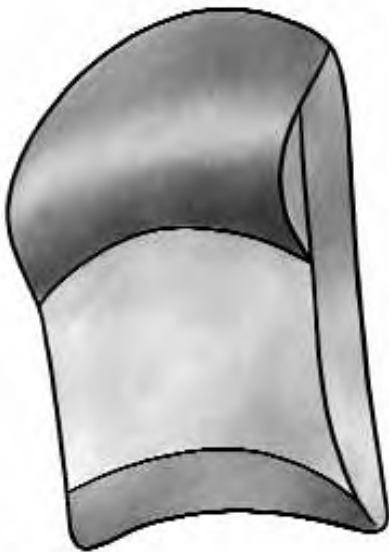

FIGURE 17-6 Combination Tarsal Platform and Metatarsal Rocker– **Action:** Deflects pressure from affected metatarsal heads; Shifts the treadline away from the metatarsal heads.
Indications: Multiple lesions distributed over the forefoot.

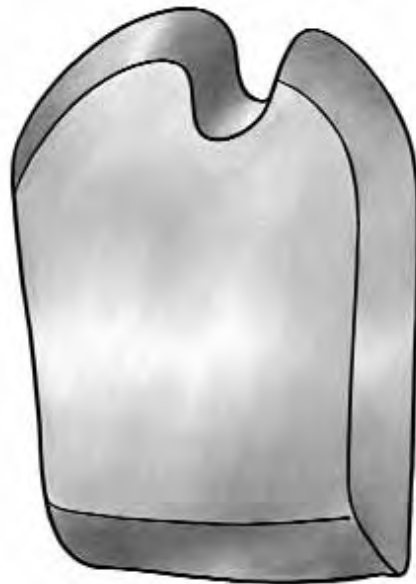


FIGURE 17-7 Plantar Metatarsal Pad (PMP)– **Action:** Deflects pressure from affected metatarsal head; Loads metatarsal shafts and unaffected metatarsal heads.
Indications: Pressure lesions affecting a rigid functioning foot (as with STJ supination).

The PMP can be modified to palliate the first of fifth metatarsal head or any other metatarsal head in isolation. The width of the PMP is extended so that the full thickness of the PMP supports the first and fifth metatarsals. An appropriate shape, conforming to the metatarsal head, is cut from the PMP and bevelled to allow the metatarsal head to be accommodated in the cut away area. The effect of a "U" or "wing" shaped section cut away from the PMP is that pressure is deflected from the vulnerable metatarsal head to the PMP and other metatarsal heads.²

Note: *If the foot is affected by aphasic subtalar pronation a PMP should not be used unless it is incorporated as an extension of a tarsal cradle (Fig. 17-3). The reason is that when the STJ pronates, the foot becomes hypermobile and demonstrates a tendency to spread and elongate as it bears weight. The instability of the foot with associated mobility of the plantar surface can result in a traumatised plantar site being forced repeatedly over the bevelled edges of the PMP. The resulting shearing stress can exacerbate the trauma.*

Moulded Insoles

These appliances should be used with care. They are best prescribed for patients with gross rigid deformities or those for whom surgical correction has resulted in multiple joint fixation. The function of a moulded insole is to maximise the weight-bearing surface and thereby reduce the risk of high pressure lesions at vulnerable prominences. The manufacture of a moulded insole is based on a static impression. They are suitable therefore for people who present with feet that only function as a supportive prop and are not expected to facilitate the more dynamic functions of the normal foot.

Note: *Moulds should always be taken with the patient fully weight bearing so that a valid impression of the foot's surface can be recorded.*

The method of manufacture limits the usefulness of the moulded insole. Moulds are made from a static impression but it must be considered that the foot may not be static on weight bearing. Before any appliance is made to accommodate the shape of the foot, therefore, it should be ascertained whether the foot is mobile during stance. It is not sufficient to determine only whether the foot can dorsiflex and plantarflex. It must also be ascertained to what extent the foot responds to frontal plane demands. If the foot everts on weight bearing the foot could be at risk in a moulded insole.

The entire plantar aspect will shift laterally and distally thereby potentially placing vulnerable sites out of the areas moulded for their protection.

CONCLUSION

Mechanical problems require mechanical solutions. The more that can be understood about the underlying mechanisms that lead to tissue breakdown, the more we will be able to address the cause. However, man is not merely a machine. Function relates, in the first instance, to managing the challenge to the intellect and emotions of social and economic realities. There is a hierarchy for preservation against physical realities: hunger, shelter and security head that hierarchy. While poverty persists our efforts to save the feet of people will, therefore, depend on pragmatic solutions. Foot orthoses will not solve all problems. They will at best be an adjunct to treatment, but the therapies suggested here follow a simple and pragmatic methodology that is known to help.

GLOSSARY OF TERMS RELATING TO ORTHOTIC THERAPY

KINETICS: The study of forces that cause motion

MASS: The quantity of matter in an object. i.e.:
The number of atoms that make up an object will remain the same no matter if that object is affected by gravity or not.

CENTRE OF GRAVITY: This is an imagined point in an object around which all other parts of the object exactly balance each other so that, if this point is supported, the object will remain at rest. In the body, its location will vary according to the position of body segments. For most practical purposes the location of the CENTRE OF GRAVITY has the same location as the CENTRE OF MASS.

CENTRE OF MASS: An imagined point in an object that moves in the same direction as any particle would move if it was responding to the same forces.

GROUND REACTION FORCE: The force that acts on a body as a result of the body's contact with the ground.

SI UNITS: (System International Units) A system where mass is measured in Kilograms Length is measured in meters Time is measured in seconds.

NEWTON: 1 Newton is the force that will give a mass of 1kg. an acceleration of 1 meter per second/per second.

WEIGHT: Force due to the gravitational pull of the earth. Without gravity we would have mass but no weight.

GRAVITY: An attraction between objects. On the Earth's surface all objects are pulled toward the earth so that they have an acceleration of 9.81 m/s.

ACCELERATION: A change in velocity

$$\frac{\text{Velocity 1} - \text{Velocity 2}}{\text{Time}}$$

FORCE: Mass x Acceleration

PRESSURE: Force / Area

LOAD: To apply force

COMPRESSION: When an object is loaded by collinear forces acting on it from opposite directions to push it together.

TENSION: When an object is loaded by collinear forces which act in an opposite direction to pull the object apart.

SHEAR: When an object is loaded by forces which act on it in opposite but parallel directions.

FRICTION: Friction is the property that objects have which makes them resist being moved across one another. If two objects with flat surfaces are placed one on top of the other, the top object can be lifted without any resistance except that of gravity. But if one object is pushed or pulled along the surface of the other, there is a resistance caused by friction.

STRESS: Force that develops in an object in response to externally applied loads. Stress may be tensile if the object is subjected to tension, compressive if the object is subjected to compression or shearing if the object is subjected to shear. Normal stress changes the length of a structure. Shear stress changes the angle of a structure.

FATIGUE: The failure of tissue or other material due to loading.

REFERENCES

1. Bauman JH, Girling JP, Brand PW: Plantar pressures and trophic ulceration. J Bone Joint Surg 45-B: 652, 1963

2. Black JA: Orthoses. In Lorimer, D (Ed) Disorders of the Foot. Edinburgh: Churchill Livingstone. 2002
3. Blake R.L. and Ferguson H: The inverted orthotic technique: a practical discussion of an orthotic therapy. *J Brit Pod Med*; 48: 25-29, 1993
4. Brand P: Insensitive Feet, A Practical Handbook on Foot Problems in Leprosy. London: The Leprosy Mission, 1981
5. Bøsjen-Møller F, and Jorgensen U: The plantar soft tissues: Functional and clinical applications. In Jahhs, M.H: (Ed.) Disorders of the foot. Philadelphia: W.B Saunders and Co., 1982
6. Coleman WC: The relief of forefoot pressures using outer sole shoe modifications. In: Proceedings Int Conf Biomech Clin Kines Hand Foot. Madras: Indian Institute of Technology, 1985
7. Coleman WC: Shoe gear for the insensitive foot. *Clin Pod Med Surg* 4, 459-470, 1987
8. Cross H, Sane S, Dey A, and Kulkarni VN: The efficacy of podiatric orthoses as an adjunct to the treatment of plantar ulceration in leprosy. *Lepr Rev* 66:144-157, 1995
9. Cross H, Kulkarni VN, Dey A, Rendall G: Plantar ulceration in patients with leprosy. *J Wound Care* 5: 406-411, 1996
10. Enna SG, Brand PW, Reed JK, Welch D: The ortho-tic care of the denervated foot in Hansen's disease: a survey updated. *Orthot Prosth*, 30: 33-39, 1976
11. Ferguson H, Blake RL. Update and rationale for the inverted functional foot orthosis. *Clin Podiatr Med Surg* 11:311-37, 1994
12. Huson A: Functional Anatomy of the Foot. In: Disorders of the foot. Vol 1 ed. Jahhs M.H. W.B. Saunders and Co., Philadelphia, 1991
13. Landorf KB and Keenan A: Efficacy of foot orthoses: what does the literature tell us? *Austr J Pod Med* 32: 105-113, 1998
14. Kirby K: Effects of longitudinal Arch height on lateral ankle instability. Newsletter. R. Orthotic Laboratories, California, 1991
15. Kirby K: Plantarflexed first ray deformity. Newsletter. R. Orthotic Laboratories, California, 1991
16. Kirby K: Methods for determination of positional variations in the subtalar joint axis. *J Am Pod Med Ass* 77: 228-234, 1987
17. Kirby KA: The medial heel skive technique. Improving pronation control in foot orthoses. *J Am Podiatr Med Assoc* 82:177-88, 1992
18. Kulkarni VN, Antia NH, Mehta JA: Newer Designs in footwear for leprosy patients. *Ind J Lepr* 62:483-487, 1990
19. Mann RA: Overview of foot and ankle biomechanics. In M.H. Jahhs, Disorders of the foot. Vol 1. W.B. Saunders and Co., Philadelphia, 1991
20. Neale D, and Boyd PM: Structure and Function. In D. Neale, and I.M. Adams (Eds.): Common Foot Disorders Edinburgh: Churchill Livingstone, 1989
21. Nawoczinski DA, Birke JA, and Coleman WC: Effect of rocker sole design on plantar forefoot pressures. *J Am Pod Med Ass* 78: 455-460, 1988
22. Patil KM, Babu TS, Oommen PK, and Srinivasan H: Foot pressure measurements in leprosy and footwear design. *Ind J Lepr* 58: 357-366, 1986
23. Pollard JP, LeQuesne LP, and Tappin JW: Forces under the foot. *J Biom Eng* 5: 37-40, 1983
24. Price EW: Studies on plantar ulceration in leprosy. VI The management of plantar ulcers. *Lepr Rev* 31: 159-171, 1960
25. Rodgers MM and Cavanagh PR: Glossary of biomechanical terms, concepts and units. *Phys Ther* 64: 1886-1902, 1984
26. Root ML, Orien WP and Weed JH: Abnormal Function of the Foot. Clin Biom Vol.2. Clinical Biomechanics Corporation, Los Angeles, 1977
27. Ross WF: Aetiology and treatment of plantar ulcers. *Lepr Rev* 33:25-40, 1962
28. Ross WF: Footwear and the prevention of ulcers in leprosy. *Lepr Rev* 33:202-206, 1962
29. Ross JA: Sports medicine and injuries. In: Lorimer, D (Ed) Disorders of the Foot. Churchill Livingstone, Edinburgh, 2002
30. Schaff PS and Cavanagh PR: Shoes for the insensitive foot: The effect of a rocker bottom shoe modification on plantar pressure distribution. *Foot Ankle* 11: 129-140, 1990
31. Sims DS and Birke JA: Effect of rocker sole placement on plantar pressures. Proceedings 20th. Annual Meeting of the USPHS Professional Association, (Abstract) p. 53 Atlanta, 1985
32. Thomson CE, Campbell RH, Wood AR, Rendall GC: Adult foot disorders. In Lorimer, D (Ed) Disorders of the Foot. Churchill Livingstone, Edinburgh: 2002
33. Zhu H, Wertsch JJ, Harris GF, Loftsgaarden JD and Price MB: Foot pressure distribution during walking and shuffling. *Arch Phys Med Rehab* 72: 390-397, 1991
34. Zhu H, Harris GF, Alba HM, Wertsch JJ: Effect of walking cadence on plantar pressures. *Arch Phys Med Rehab* 76:1000-1005, 1995

Squamous Cell Carcinoma and Amputations

• R. SCHWARZ

SQUAMOUS CELL CARCINOMA

The incidence of squamous cell carcinoma in the foot is very high in patients affected with chronic plantar ulcers from leprosy.^{1,7,10-13} Those with chronic ulcers due to other neuropathic diseases appear to have a much lower incidence given the paucity of reports in the literature. The development of carcinoma in leprosy patients is due to the prolonged ulceration to which these patients are subject, especially in those patients residing in developing countries who are unable to seek medical attention early. Richardus and Smith¹⁰ found that patients with a malignant ulcer had a history of ulceration of 15 years duration. Interestingly matched controls with benign plantar ulcers had an average duration of ulceration of 26 years. The pathologic progression is similar to that seen in a Marjolin's ulcer, a squamous cell carcinoma arising in an old burn scar.⁶ The chronic attempts at wound healing over many years gradually leads to metaplastic changes, which then progress to dysplasia and finally neoplasia. As in Marjolin's ulcer, squamous cell carcinoma usually arises after a history of an ulcer being present for many years or decades. These patients often present with large fungating tumours already involving bone (Fig. 18-1), but they may also present with flat benign appearing ulcers as well. Bobhate et al¹ found that plantar ulcers in the heel are more likely to undergo malignant transformation than those in the forefoot. Any suspicious ulcer or any ulcer that fails to heal with appropriate conservative management should be biopsied. It must be kept in mind that the pathologic diagnosis

of these lesions is difficult. In one study 41% of squamous cell carcinomas had a benign diagnosis on initial biopsy.⁸ Some required up to four biopsies (the last biopsy including the foot!) to establish the diagnosis. In the same study review by four different pathologists showed considerable conflict in pathologic diagnoses, the most common benign diagnoses being corneum cutis and hyperkeratosis.

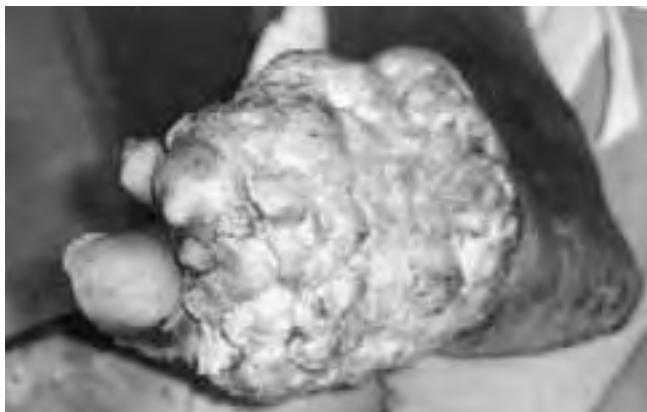

FIGURE 18-1 Fungating squamous cell carcinoma of the foot, treated with excision and coverage with medial plantary artery flap.

Obviously the best management is prevention, emphasizing again the need of appropriate counselling and footwear in those with loss of sensation in the sole. When patients present with established carcinoma, one tries to preserve as much of the foot as possible while performing a curative resection of the cancer. A minimum of 1 cm clearance of the tumour at the margins is necessary, although for late stage tumours 3-5 cm is recommended due to the deep invasion that is sometimes present.

Surgical resection margins should be checked by the pathologist, and re-excision planned if the margins are involved. In relatively early cases it may be possible to perform a curative resection without an amputation. Some cases of the heel we have treated with wide excision and a medial plantar artery or cross-leg flap for reconstruction, with no recurrence for up to 5 years. However, at present we would not recommend a cross-leg flap due to the risk of seeding tumour to the other leg and the development of better, local flaps such as the medial plantar artery flap (see Chapter 16). Fritschi reports patients treated with excision and skin grafting with no recurrence for years.⁴

The majority of patients will require an amputation of some kind. If on one side of the forefoot, the half bearing the cancer is excised in a wedge and the other side is used to close the wound after removal of the metatarsals.⁴ This will preserve some toes for the patient. I would recommend tendon Achilles lengthening after this procedure, which is essentially a Lisfranc's amputation. Other patients will require a Boyd's or Syme's amputation to achieve a curative resection (see below for technique).¹³ Only in large tumours involving the heel will a below knee amputation be necessary. McDonald reports that 40% required a foot saving amputation and 52% required a below-knee amputation.⁸ 8% were treated with local excision and flaps. No recurrences were reported.

Patients frequently present with popliteal, femoral and inguinal lymphadenopathy.^{1,12} In most cases this is due to inflammatory lymphadenopathy. This can be diagnosed by fine-needle aspiration cytology, or the surgeon can wait until after excision of the tumour to see if the lymphadenopathy resolves. In those with proven metastatic disease in the groin, a block dissection of the femoral lymph nodes is carried out, although these patients have a poor prognosis.

AMPUTATIONS

While all reasonable efforts to preserve a foot should be expended, some patients will present with a foot that is no longer salvageable. This may be due to destruction of the foot by infection, gross bony destruction by neuropathic bone disease or osteomyelitis, or massive plantar ulceration. Amputation does not mean failure but should be approached with the goal of preserving as much quality weight-bearing sole as possible. Especially for those patients living in remote areas, being able to walk without a special prosthesis is a great advantage. Amputations at various levels are described below. Other than the toe amputation all should be done under tourniquet control with pre-operative exsanguination, releasing the tourniquet prior to skin closure to check haemostasis. A single dose of pre-operative antibiotic, covering gram-positive organisms, should be given.

Toe Amputation

Fish-mouth flaps are created on the dorsal and ventral surfaces preserving all fat, starting the incision at the level of intended bone section and making the plantar flap slightly longer than the dorsal flap. Tendons are divided as far proximally as possible. In the great toe the sesamoids are removed. Digital nerves are divided proximally and the vessels ligated and divided. If the amputation is through the level of the metatarsophalangeal joint the joint capsule must be resected but the articular cartilage can be left. Skin is closed in one layer.

Ray Amputation

This is of benefit to preserve as much of the distal weight-bearing foot as possible. It is usually used on the first and fifth digits but can be used for multiple digits.

Technique: Fishmouth flaps are raised at the base of the digit and a longitudinal dorsolateral-

al incision is then extended to the base of the metatarsal. Part or all of the metatarsal is removed and the tendons are then divided proximally. Skin is closed in a single layer.

Transmetatarsal Amputation

This is seldom indicated in leprosy but is more common in diabetes due to vascular insufficiency. A long plantar flap is raised just distal to the level of the metatarsophalangeal joints and with a dorsal flap extending just beyond the mid-metatarsal level. The flaps are slightly longer on the medial side because of the greater foot thickness here. The metatarsals are divided taking care to preserve at least the proximal quarter. Skin is closed in two layers with a drain left in that is removed in 48 hours.

At times the patient may present with advanced infection and destruction of the forefoot but preserved toes. Patients like their toes and if possible the surgeon should try to preserve them. In this situation the metacarpals can be excised as needed, the edges smoothed with a file, and any plantar ulcerations excised and closed. The dorsal wounds are left to close on their own and may be skin grafted after an appropriate time interval to speed healing.

No special footwear is needed.

Lisfranc's Amputation

This procedure is indicated in severe forefoot destruction. A fishmouth incision is made distal to the tarso-metatarsal joints and amputation is made through this level. The incision can be closed by either the plantar or dorsal skin flap, and if there is a shortage of skin due to infection the wound can be left to close by secondary intention. The foot retains dorsi-flexion function, and no special footwear is needed. The patient may request a filler in the toe to fill out the shoe and prevent it from "flapping".¹⁶

Boyd Amputation

This gives a more functional foot than a Pirigoff as the weight bearing area of bone is larger and the weight bearing skin is sole rather than the skin of the back of the heel. It is commonly used for squamous cell carcinoma of the forefoot.

Technique: Starting at a point just anterior and one cm inferior to the distal medial malleolus, a long flap is made on the sole just distal to the fifth metatarsal base, ending at a point at the tip of the lateral malleolus (Fig. 18-2).² The dorsal flap is made at the level of the talo-navicu-

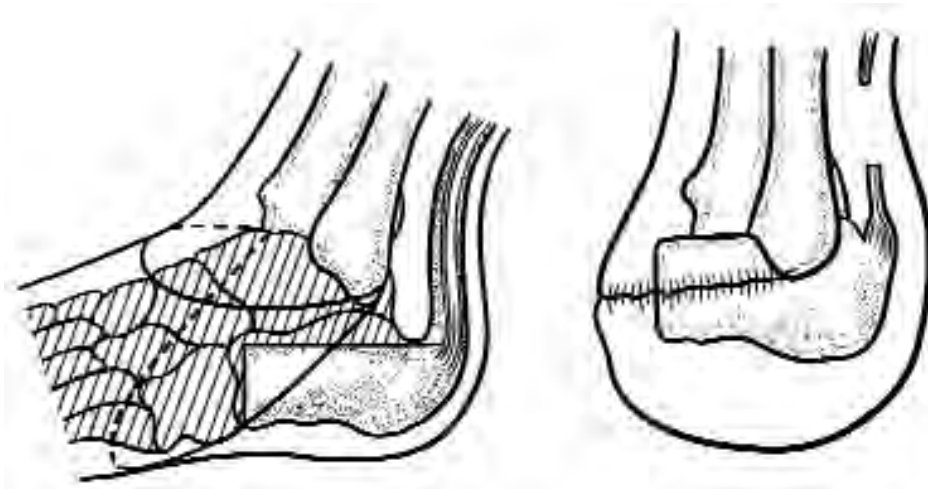


FIGURE 18-2 Boyd Amputation.

lar joint. The distal foot is removed through the midtarsal joints. The talus is removed according to the technique of Whitfield. In this the talus is grasped, pulled inferiorly and the ligaments superior to the talus are divided. Lateral ligaments are then divided, after which the inferior and finally the posterior attachments are divided. The calcaneus is divided just distal to the peroneal tubercle and the superior surface cut off transversely with an osteotome. The distal tibial articular surface is removed and the malleoli are trimmed on their inner surfaces to fit the calcaneus. Tendons and the medial and lateral plantar nerves are divided high. The calcaneus is then shifted slightly forward inserted into the mortise and fixed with a Steinman pin from the heel. Skin is closed in two layers with a drain in place that is removed in 48 hours. A plaster is placed and left for three months. The pin is removed at one month and weight bearing is commenced. The walking plaster is left until the arthrodesis is complete, usually by three months.

Pirogoff Amputation^{9,16}

While not as functional as the Boyd, it is possible to perform a Pirogoff amputation with a shorter ventral flap, allowing salvage of the foot in certain cases. Weight bearing occurs on the skin covering the back of the heel, similar to a Syme's amputation.

Technique: Starting at a point just anterior to the medial malleolus, the sole flap is cut at the level of the talo-navicular joint, ending 1 cm above the lateral malleolus (Fig. 18-3). The dorsal flap cut at the level of the talo-navicular joint. The distal foot is removed through the midtarsal joints and the talus removed as in the Boyd amputation. The ankle joint articular cartilage is removed as for the Boyd amputation. The calcaneus is cut at a right angle through the neck, or more proximally just anterior to the posterior tubercle. In this case the calcaneus is transected at an angle 30° to the long axis of the tibia, although this angle can be varied. The calcaneus is then rotated forward to oppose the anterior calcaneal surface to the ankle mortise and fixed in place with a Steinman pin. Skin is closed in two layers with a drain in place, which is removed at 48 hours. A plaster is applied. The pin is removed at one month. The plaster is removed at three months and weight bearing commenced.

Syme's Amputation

A Syme's amputation is indicated if the sole skin is insufficient to preserve the calcaneus. It has the disadvantage of not entirely weight-bearing on sole skin. It requires a special prosthesis to walk a significant distance, but can be used for very short distances without a prosthesis such as to go to the toilet at night. It has

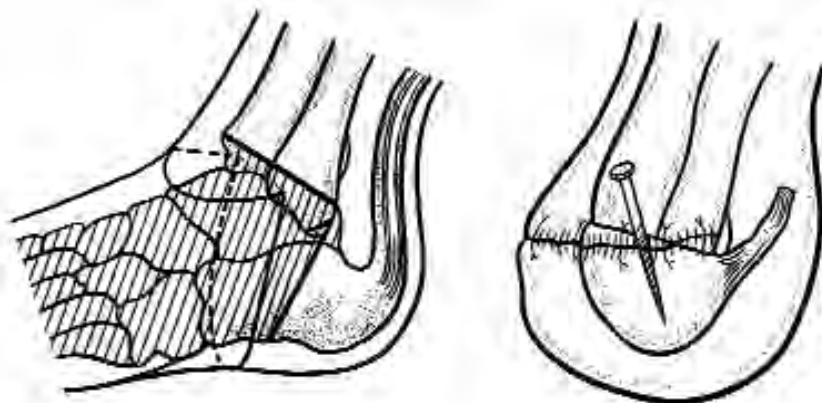


FIGURE 18-3 Pirogoff amputation.

a tendency to form a pseudobursa, making the weight-bearing skin pad very mobile. If this occurs it can be excised, but it has a tendency to re-form. Common causes of failure are flap necrosis due to overzealous trimming of the dog-ears and posterior migration of the heel pad.⁴

Technique: Starting 1 cm inferior to the medial malleolus, the plantar flap is made at the level of the mid-calcaneus, ending at the tip of the lateral malleolus (Fig. 18-4). The anterior flap is made at the level of the ankle joint. The medial and lateral ligamentous attachments of the ankle are divided starting with the blade in the joint space, taking care not to damage the vessels. A bone hook is placed in the talus to place it in extreme equinus after which the posterior ankle joint capsule and then the Achilles tendon are divided. The plantar flap is taken off the calcaneus in a sub-periosteal plane, being careful to preserve the blood supply to the flap. The foot is then removed through the ankle joint. Soft tissues are dissected off the distal tibia and fibula with the periosteal elevator. The periosteum is then divided sharply 6 mm above the joint line and the bone then divided at this level, perpendicular to the line of the tibia. All tendons and the medial and lateral plantar nerves are divided high and vessels are tied. The heel flap is brought forward to be sutured to the anterior flap ensuring that the suture line is anterior to the weight-bearing surface. Wagner has described a technique to

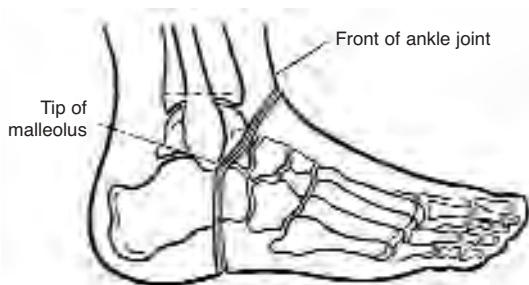


FIGURE 18-4 Syme's amputation- skin flaps. (from Richardson⁹, used with permission)

prevent the posterior migration of the heel flap.^{8,15} Holes are drilled through the anterior edge of the tibia and fibula and the fascia of the heel flap is then sutured to the bones through these holes. A drain is left and removed at 48 hours, and a bulky dressing applied. Weight bearing is commenced at one month with a prosthesis, or a prosthetic cast can be applied after the drain has been removed and early ambulation commenced. A patient with a left Syme's amputation and a right Pirigoff amputation is shown in Fig. 18-5.

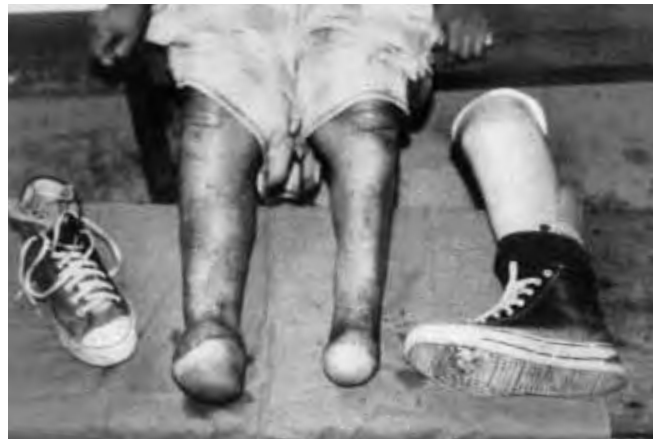

FIGURE 18-5 Patient with a left Syme's amputation and a right Pirigoff amputation. The patient is able to ambulate with bare feet, but uses a patellar weight bearing prosthesis on the left when walking long distances.

Below-Knee Amputation

If the septic or other destructive process makes a more distal amputation impossible, the surgeon should carry out a below-knee amputation without unnecessary delay so that the rehabilitation process can start as soon as possible. For amputations for peripheral vascular disease there are many factors regarding the estimation of blood supply to the calf skin that can be used to predict flap survival and wound healing. The reader is referred to a surgical textbook for a full discussion of these issues.¹⁴

In amputations for neuropathy the blood supply is generally good and good wound healing can be expected in almost all cases. In those patients with an active septic process in the foot at the time of amputation, there is an increased likelihood of wound infection, especially if cellulitis is extending up the calf. In these cases one should consider a guillotine amputation at the level of the ankle as an initial procedure. The definitive procedure can then be carried out several days later after the infection has been controlled. Both the standard Burgess³ amputation and the fishmouth amputation have been reported, but only the Burgess amputation is described in the following text. The fishmouth amputation is shown and briefly described in Figure 18-6. In non-ischaemic limbs tension myoplastic procedures are performed or even firmer stabilization with myodesis. These are contraindicated in the ischaemic limb as they may further compromise a tenuous blood supply. Preserving adequate length of the stump is important, as it has been shown that a short stump leads to

increased energy expenditure of ambulation.⁵ **Technique:** A point is marked 12.5-17 cm below the joint line, or 10-12.5 cm in ischaemic limbs, depending on body height.¹⁴ Points are then made at the mid-point of the calf on both medial and lateral sides 1 cm proximal to the first point and the points connected (Fig. 18-7). The width of the calf is then measured, and the length of the posterior flap is then marked at this length plus 1 cm. The anterior flap is 1 cm long. The anterior flap is then cut down to periosteum and the periosteum is then raised proximally. Muscles of the anterior compartment are divided. The anterior tibial vessels and peroneal nerve are divided and then ligated above the level of bone transection, first pulling on the nerve to allow them to retract well above the amputation levels. The tibia is cut 1 cm proximal to the tip of the anterior flap, beveling the anterior aspect and filing the edges smooth. After dividing muscles in the lateral compartment the fibula is divided 1 cm above the level of the tibial amputation. The posterior tibial vessels are then doubly tied and

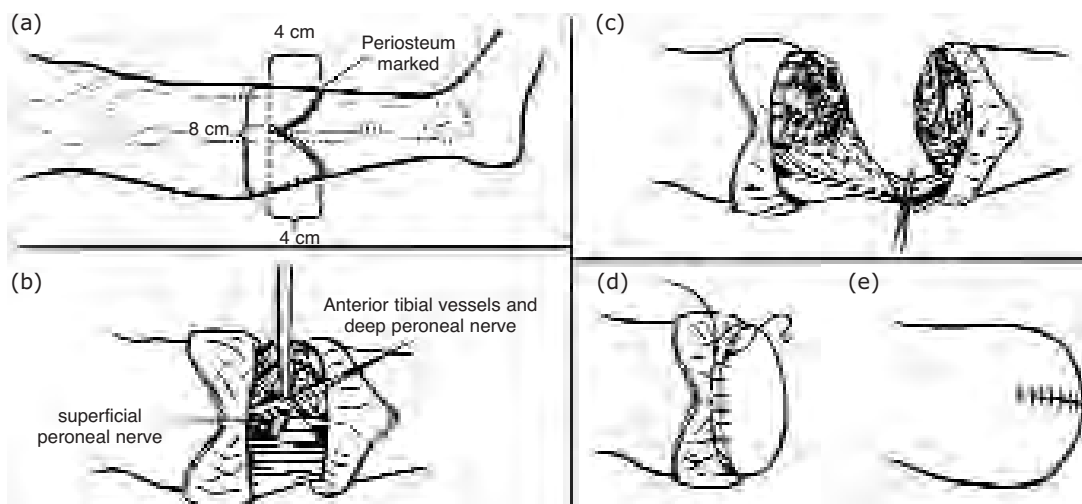


FIGURE 18-6 Below-knee amputation for non-ischemic limbs. **a.** Skin incisions creating equal anterior and posterior flaps, each one half of the anteroposterior diameter of the leg. **b.** Anterior tibial vessels divided. Tibial, deep and superficial peroneal nerves all divided and ligated high to avoid painful neuromas. **c.** Fashioning of long posterior myofascial flap. **d.** Posterior myofascial flap sutured to periosteum anteriorly. **e.** Skin closure (From Tooms¹⁴, used with permission).

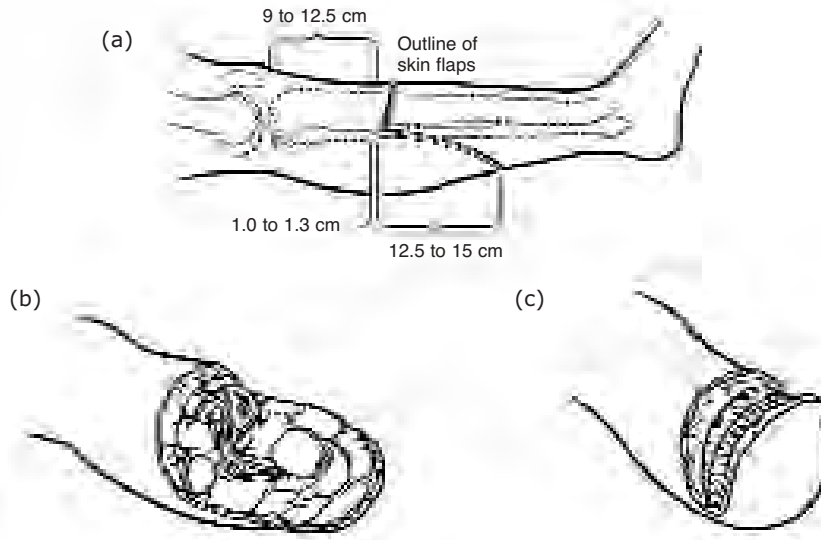


FIGURE 18-7 Burgess' below knee amputation **a.** Skin incisions. **b.** Distal leg removed and muscles bevelled. **c.** Posterior fascia sutured to periosteum and anterior fascia (Modified from Tooms¹⁴, used with permission).

divided. The posterior tibial nerve is divided high and allowed to retract. The posterior muscles are divided, leaving only gastrocnemius muscle mass attached to the posterior flap so that the stump will not be too bulky. An amputation knife is used to bevel this muscle mass. Gastrocnemius tendon is divided 1 cm proximal to the level of the skin flap, taking care not to separate the skin from the underlying muscle. The wound is well irrigated and hemostasis obtained after release of the tourniquet. A drain is left and removed at 48 hours. The posterior fascia is sutured with some tension to the anterior fascia. Skin is then closed with interrupted sutures and a padded bandage placed, ensuring that this does not compromise circulation to the stump. Stump bandaging is commenced at one week and continued until the stump is ready for prosthesis fitting. The stump will shrink over the first three to four months, after which permanent prosthesis fitting can be done. A temporary prosthesis can be fitted in the interim.

References

1. Bobhate SK, Madankar ST, Parate SN, Chaudhary RK, Kumbhalkar DT: Malignant transformation of plantar ulcers in leprosy. *Ind J Lepr* 65:297-303, 1993
2. Boyd, HB: Amputation of the foot, with calcaneotibial arthrodesis. *J Bone Joint Surg* 21:997-1001, 1939
3. Burgess EM: Prevention and correction of fixed equinus deformity in mid-foot amputations. *Inter-Clin Bull* 6:20, 1966
4. Fritchi, EP: *Surgical Reconstruction and Rehabilitation in Leprosy*. The Leprosy Mission, New Delhi, 1984
5. Gonzales EG, Corcoran PJ, Reyes RI: Energy expenditure in below knee amputee: correlation with stump length. *Arch Phys Med Rehabil* 55:111, 1974
6. Konigova R, Rychterova : Marjolin's ulcer. *Acta Chir Plast* 42:91-4, 2000
7. Kumaravel S: Neoplastic transformation of chronic ulcers in leprosy patients--a retrospective study of 23 consecutive cases. *Ind J Lepr* 70:179-87, 1998
8. McDonald M: Squamous cell carcinoma in plantar ulcers. In *Book of Abstracts of the First Asian Leprosy Congress*, Agra, Nov, 2000

9. Richardson EG, Tooms RE: Amputations about the foot. pp 1973-1990. In Canale ST (ed) Campbell's Operative Orthopaedics, 9th ed. Mosby, St. Louis, 1998
10. Richardus JH, Smith TC: Squamous cell carcinoma in plantar ulcers in leprosy. A case control study. *Lepr Rev* 64:270-4, 1993
11. Richardus JH, Smith TC: Squamous cell carcinoma in chronic ulcers in leprosy: a review of 38 consecutive cases. *Lepr Rev* 62:381-8, 1991
12. Sane SB, Mehta JM: Malignant transformation in trophic ulcers in leprosy: a study of 12 cases. *Ind J Lepr* 60:93-99, 1988
13. Soares D, Kimula Y: Squamous cell carcinoma of the foot arising in chronic ulcers in leprosy patients. *Lepr Rev* 67:325-9, 1996
14. Tooms, ET: Amputations of the lower extremity. Pp532-541. In Canale ST (ed) Campbell's Operative Orthopaedics, 9th ed.. Mosby, St. Louis, 1998
15. Wagner FW Jr: Management of the diabetic-neurotrophic foot: Part II. A classification and treatment program for diabetic, neuropathic and dysvascular foot problems. In Cooper RR (ed): AAOS Instructional Course Lectures, vol 28. CV Mosby, St. Louis, 1979
16. Warren GW, Nade S: The Care of Neuropathic Limbs. Parthenon Publishing Group, 1999

Other Reading

1. Pinzur MS, Kaminsky M, Sage R, Cronin R, Osterman H: Amputations at the middle level of the foot: A retrospective review. *J Bone Joint Surg* 68A: 1061-70, 1986
2. Sage R, Pinzur MS, Cronin R, Preuss HF, Osterman H: Complications following mid-foot amputation in neuropathic and dysvascular feet. *J Am Pod Med Ass* 79:277-81, 1989